



## CLINICAL IMAGES

## Cutaneous cryptococcosis erroneously diagnosed as *Histoplasma capsulatum* infection

Geoffrey A Chipungu, Sean J Christians, Stephen P Oliver

A 31-year-old patient with stage 4 HIV/AIDS presented with recurrent painful skin ulcers for more than 8 months. These would start as subcutaneous skin nodules, later becoming fluctuant and suppurating and then healing spontaneously (Fig. 1). The patient had lesions on the left wrist, left posterior thigh, right axilla, right posterior calf and right upper eyelid. He had also been diagnosed with extrapulmonary tuberculosis and had been on highly active antiretroviral therapy (HAART) for 8 months and antituberculosis medication (continuation phase). After initial poor adherence to both groups of drugs, compliance had improved. The CD4 count at baseline was 16 cells/ $\mu\text{l}$  and the latest result was 80 cells/ $\mu\text{l}$ . Histological analysis of a biopsy specimen taken from the right upper eyelid lesion showed granulation tissue with some acute inflammation. Fungal spores were seen in the exudates and stains revealed 'capsule-deficient' fungi that were first thought to be *Histoplasma*, and were reported as such.

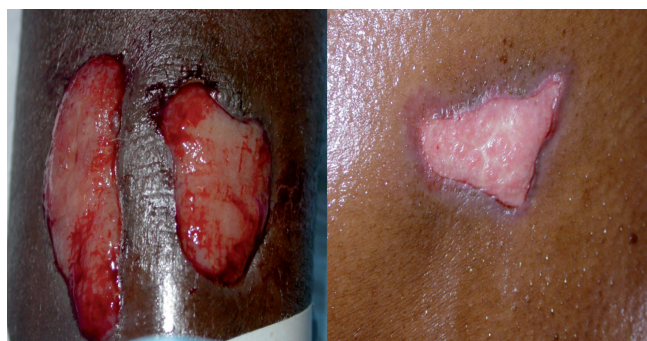

Fig. 1. Lesions at presentation: (left) granulomatous raised ulcers on the elbow; (right) spontaneously healing ulcer on the left side of the neck.

G A Chipungu obtained his MB BS from University of Malawi's College of Medicine where he is employed as an assistant lecturer. He currently holds a supernumerary registrar post in Medical Microbiology at the National Health Laboratory Service (NHLS), Groote Schuur Hospital. S J Christians graduated from the University of Limpopo (formerly MEDUNSA) with an MB ChB and is now a registrar in the Department of Dermatology at Groote Schuur Hospital. S P Oliver is a principal specialist and acting head of department in Medical Microbiology at the NHLS, Groote Schuur Hospital. All the authors are affiliated to the Faculty of Health Sciences, University of Cape Town.

Corresponding author: G A Chipungu (geoffrey.chipungu@uct.ac.za)

Two pus swabs were sent for bacterial, fungal and mycobacterial culture. Gram stains revealed moderate numbers of (or ++ ) pus cells and the presence of fungal elements. *Cryptococcus neoformans*, which was sensitive to fluconazole, was isolated from both pus swabs and the biopsy specimen. A mixture of Gram-negatives and Gram-positives were thought to be colonisers. Ziehl-Neelsen stain and mycobacterial culture were negative. A diagnosis of disseminated cryptococcosis was made and treatment with fluconazole was commenced. Clinicians pointed out the discrepancy between the two reports. Another section was therefore stained with mucicarmine<sup>1,2</sup> and the diagnosis was revised to *C. neoformans* infection (Fig. 2). The possibility of coinfection was ruled out by means of extended fungal culture, and the lesions responded clinically to fluconazole.

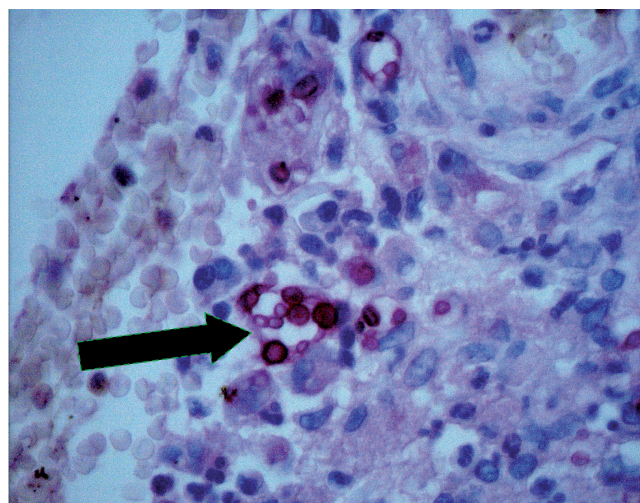


Fig. 2. Mucicarmine-stained histology section showing a group of *Cryptococcus* cells with a dark-staining capsule against a brighter background (black arrow). Note the variation in size of the yeast cells and the difference in capsular thickness (seen with cutaneous cryptococcosis).

### Discussion

Cryptococcal infection, usually presenting as meningoencephalitis, is being diagnosed more frequently in sub-Saharan Africa because of the HIV/AIDS pandemic.<sup>3</sup> However, presentations may vary and include skin lesions, lung infections and infections of other organs.<sup>3-5</sup> In this patient the possibility of central nervous system involvement was



ruled out by a negative lumbar puncture. Differential diagnosis included disseminated tuberculosis, carcinoma (primary or metastasis), *Histoplasma capsulatum* or other fungal infections, Kaposi's sarcoma and herpes simplex virus (with secondary infections).

In stage 4 HIV infection patients are so immunocompromised that opportunistic infections with multiple organisms presenting in atypical ways and at unusual sites can occur. This may present a diagnostic dilemma, and choosing empirical treatment is difficult as all these conditions merit different and sometimes potentially toxic treatment. Since histological examination can be nonspecific in the case of fungal infections, diagnosis is primarily by means of culture, with morphology,

pattern of growth, biochemical reactions and automated systems used to arrive at a diagnosis. In this case a discrepancy between laboratories meant either a misdiagnosis or the rare occurrence of a mixed infection,<sup>2</sup> which was unlikely as three specimens all cultured the same organism. The need for both histological and microbiological investigations is highlighted.

1. Vance AM. The use of the mucicarmine stain for a rapid presumptive identification of *Cryptococcus* from culture. *Am J Med Technol* 1961; 27: 125-128.
2. Ferry T, Ponceau B, Gaultier JB, et al. Disseminated cryptococcosis and histoplasmosis co-infection in a HIV-infected woman in France. *J Infect* 2005; 51: e173-e176.
3. Mandell GL, Bennett JE, Dolin R. *Mandell, Douglas and Bennett's Principles and Practices of Infectious Diseases*. 5th ed. Philadelphia: Churchill Livingstone, 2000: 2707-2718.
4. Murakawa GJ, Kerschmann R, Berger T. Cutaneous cryptococcus infection and AIDS. Report of 12 cases and review of the literature. *Arch Dermatol* 1996; 132: 545-548.
5. Vasanthi S, Padmavathy B. Cutaneous cryptococcosis among HIV infected patients. *Indian Journal of Medical Microbiology* 2002; 20: 165-166.

## HISTORY OF MEDICINE

# Herophilus of Chalcedon and the practice of dissection in Hellenistic Alexandria

Goran Štrkalj, David Chorn

The dissection of human cadavers is a complex topic that can be comprehended only if a number of factors are taken into account, as illustrated by the example of Herophilus of Chalcedon, who was the first dissector in the Western medical tradition. The social, cultural, political and intellectual climate of Hellenistic Alexandria in the third century BC provided Herophilus with opportunities to dissect – and possibly vivisect – human bodies. He was thus able to make an unprecedented number of anatomical discoveries and accompanying accurate descriptions. Subsequent changes in Alexandrian society and its intellectual climate saw the rapid demise of the practice of dissection – its resurgence occurring only some 15 centuries later.

*Goran Štrkalj is a physical anthropologist and Senior Lecturer in the School of Anatomical Sciences, University of the Witwatersrand. The history of science is one of his main research interests.*

*David Chorn was previously Anatomy Teaching Prosector in the School of Biomedical Sciences, Queen's Medical Centre, Nottingham, UK, and is currently Senior Tutor in Anatomy in the Faculty of Health Sciences at Wits.*

Corresponding author: G Štrkalj (goran.strkalj@wits.ac.za)

Probably no issue in medicine has caused as much controversy and dilemma – scientifically, educationally and morally – as dissection of the human cadaver.<sup>1-5</sup> For most of recorded history and within the various medical traditions, dissection of human bodies was forbidden and often harshly punishable by law. Even when dissection was permitted and tolerated, '... the motivating reasons for doing them were by no means uniform'.<sup>6</sup> It was a long time before human dissection was introduced into Western medicine. Yet, for a brief period, two scientist-physicians in Hellenistic Alexandria during the third century BC, Herophilus and Erasistratus, performed such dissections. Only some 15 centuries later was the practice re-introduced in Western medicine.<sup>7</sup>

This paper focuses on the period during which dissection was known to have been performed for the first time, and, specifically, on one of its two main protagonists, Herophilus of Chalcedon. The sudden inception of human dissection was remarkable and can only be understood fully if complicated and interrelated scientific, medical, social, political and cultural factors are considered. Likewise, some current dilemmas concerning dissection<sup>8</sup> can be better comprehended if considered in their contextual complexity.

## Dissection in antiquity

Despite the paucity of historical documentation, it may fairly be stated that the Alexandrian physicians were the first in the