



CLINICAL IMAGES

Fatal vascular retroperitoneal injury following bone marrow biopsy

Inchien Chamisa

A 29-year-old man was referred with a 6-year history of shortness of breath on exertion and palpitations. He had central and peripheral cyanosis, finger clubbing, a pulmonary thrill with ejection click and a loud second pulmonary heart sound. An echocardiogram showed an endocardial cushion defect, single atrium, right-sided aorta, pulmonary hypertension, tricuspid regurgitation and situs inversus with levocardia. The patient's platelet count was $62 \times 10^9/l$, and he therefore underwent a bone marrow trephine biopsy taken from the left posterior iliac fossa. An hour after the procedure he developed sudden abdominal pain, vomiting and hypovolaemic shock with signs of generalised peritonitis. A computed tomography (CT) angiogram revealed a false aneurysm with extravasation from the left superior gluteal artery with a massive pelvic retroperitoneal haematoma (Fig. 1). Embolisation of the left superior gluteal artery was unsuccessful. He developed an abdominal compartment syndrome. Surgical intervention was not undertaken because of his cardiac morbidity and he died 2 days after the bone marrow biopsy.

Discussion

Bone marrow aspirate and trephine biopsy are thought to be safe procedures. Although some hazards are recognised, the true incidence of the adverse effects was unknown until an investigation by members of the British Society of Haematologists,¹ prompted by the death of a patient in 2001 as a result of retroperitoneal haemorrhage after an aspirate and a trephine biopsy from the posterior iliac fossa.²

This survey of 54 890 procedures included 26 adverse events, 1 death directly attributable to the procedure and 1 death from sepsis that may have been indirectly attributable to the procedure. The most common adverse event was bleeding (14 cases). Since serious adverse events were reported in less than 0.05% of procedures they can be regarded as rare. Only 2 deaths have been reported in the UK over a period of 30 years. The common complications of this procedure include bleeding, infection and chronic pain. In these cases haemorrhage was associated with risk factors (myeloproliferative disorders, aspirin, platelet dysfunction, thrombocytopenia, obesity and

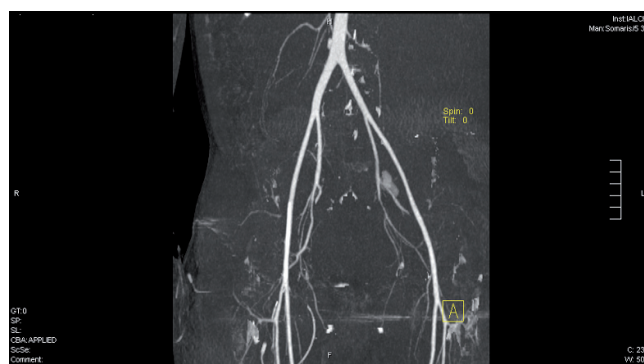


Fig. 1. CT angiogram showing a false aneurysm and extravasation from the left superior gluteal artery.

disseminated intravascular coagulation) and the patients required sustained blood transfusion. Some of them developed secondary infection and subsequently died. Surveys^{2,3} suggest that retroperitoneal haemorrhage may be more hazardous than haemorrhage into the buttock, possibly because of delayed diagnosis. In patients with retroperitoneal haemorrhage, embolisation of a bleeding vessel may obviate the need for hazardous surgery. Fatal complications have been reported following sternal aspirations resulting in cardiac tamponade.

Our patient sustained laceration to the left superior gluteal artery. Superior gluteal artery laceration as a complication of iliac crest bone graft surgery was first described by Kahn³ in 1978. Recommended management of superior gluteal artery or vein injuries has included direct pressure, surgical procedures and angiographic embolisation. A surgical technique to control bleeding from the superior gluteal artery has been described.⁴ This technique involves extension of the posterior iliac bone graft incision, detachment of the origin, and reflection of the gluteus maximus thus providing excellent exposure for haemostasis of the iatrogenic laceration of the superior gluteal artery. This technique is simple and effective and may prevent the need for transperitoneal and retroperitoneal approaches or angiographic embolisation. It allows control of a haemorrhage by a simple extension orthopaedic exposure.

This method of exposure was an option for this patient, for whom major surgery posed a high risk. However, following unsuccessful embolisation, surgical intervention was not undertaken because of his cardiac morbidity.

Dr Chamisa is a general surgeon currently working at Prince Mshyeni Hospital, Durban. He did his postgraduate training in Zimbabwe, South Africa, Scotland, England and Wales. His interests include evidence-based medicine.

Corresponding author: I Chamisa (charms@doctors.org.uk)

April 2007, Vol. 97, No. 4 SAMJ

1. Bain BJ. Bone marrow biopsy morbidity and mortality. *Br J Haematol* 2003; 121: 949-951.
2. Bain BJ. Bone marrow biopsy morbidity: review of 2003. *J Clin Pathol* 2003; 58: 406-408.
3. Kahn B. Superior gluteal artery laceration, A complication of iliac bone graft surgery. *Clin Orthop* 1979; 140: 204-207.
4. Shin AY, Moran ME. Superior gluteal artery injury secondary to posterior iliac crest bone graft harvesting. A surgical technique to control haemorrhage. *Spine* 1996; 21: 1371-1374.