



Circumcision complications associated with the Plastibell device

J Lazarus, A Alexander, H Rode

To the Editor: Sociocultural or non-medical circumcision continues to be a common practice in the Western Cape. The Plastibell (Hollister Inc., Libertyville, Ill., USA) is the most frequently used device in the local community setting. Hollister South Africa (Pty) Ltd sold 6 050 Plastibell devices in South Africa in 2003. Popularity of the device can be ascribed to its claimed 'ease of use'. It involves a technique that can be performed under local anaesthetic.

Complications associated with circumcision are considered rare and usually trivial.¹ Our institution deals with these often not-insignificant postoperative problems. We set out to review our recent experience.

Method

A retrospective folder review was undertaken to assess the outcome of circumcisions done in hospital and the complications of those done in the community. Records were drawn from ward and operative databases.

Results

Between January 1999 and December 2005, 120 circumcision procedures were recorded in our operative database. Folders for 95 boys were available for review. Seventy-nine hospital circumcisions were performed. Twenty complications were managed surgically, arising from 4 hospital and 16 community circumcisions.

The indication for hospital circumcision was phimosis in 46 children (58%), social/religious ($N = 12$, 16%), social indication in a child with other medical problems ($N = 10$, 13%), recurrent urinary tract infections ($N = 6$, 8%), and paraphimosis ($N = 5$, 6%).

Of the 79 hospital circumcisions, 4 were complicated. Two revisions were required, and 1 postoperative bleed and 1 meatal stenosis were seen.

We treated 16 boys who had complications from community circumcision using the Plastibell device. Seven boys had postoperative bleeding, requiring evacuation of haematoma and secondary suturing. Four had sepsis requiring surgical toilet. Five miscellaneous problems were seen, including the

Plastibell ring failing to separate and redo circumcision for secondary phimosis.

Discussion

Plastibell has established itself as an acceptable form of circumcision. Fig. 1 shows the operative technique (courtesy of Hollister South Africa).

Initial randomised studies² have documented equivalent outcome (complications and cosmetic appearance) with routine circumcision. Later reviews have cited an increased rate of infection with the Plastibell device. The reason for this is unclear, but may be related to the necrosis and sloughing of tissue required with this type of circumcision.¹

Plastibell complication is reported to be 2 - 3%.³ Most complications are minor, related to bleeding and superficial sepsis. However, case reports of significant complications have been documented, including necrotising fasciitis, urine retention and ischaemic necrosis of the glans.¹

We found bleeding to be the commonest Plastibell complication (44%). Close attention to ensuring that the ligature is sufficiently tightly tied is needed to prevent bleeding (Fig. 2).

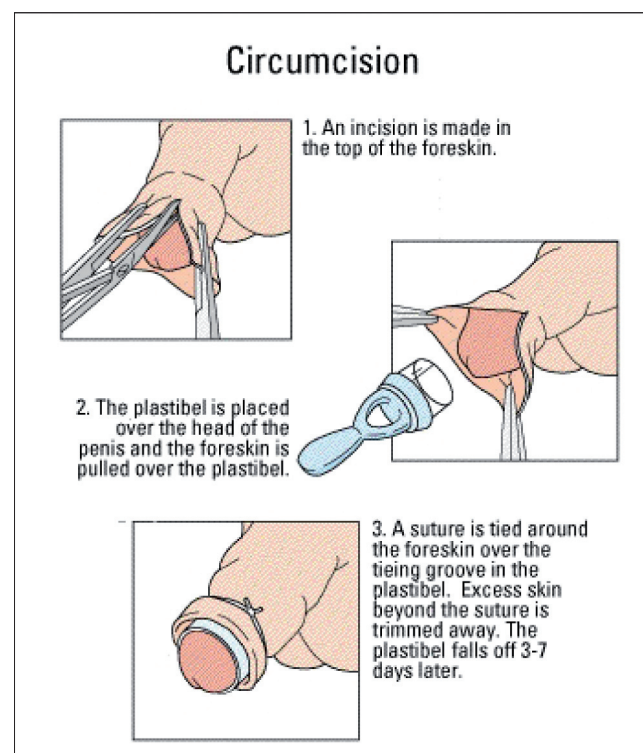


Fig. 1. Technique of Plastibell circumcision.

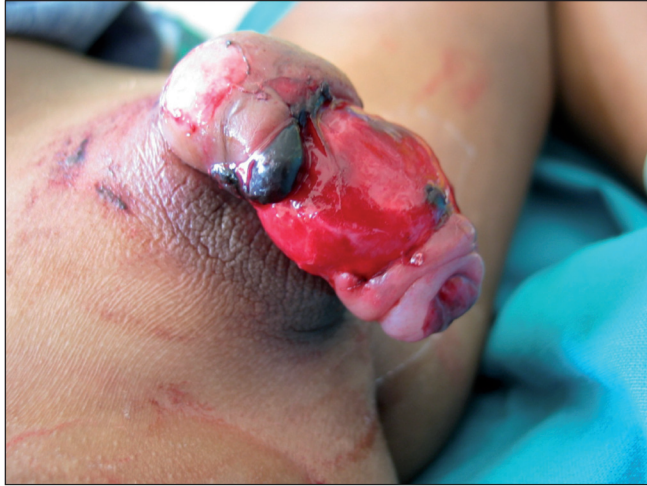

Fig. 2. Post-Plastibell separation and bleeding.

Choosing the correct size of Plastibell is crucial. Hollister advises that a too-small fit can cause tissue strangulation and necrosis, and that using one that is too large may result in too much foreskin being removed and penile denudation.

Conclusion

Although widely practised, Plastibell circumcision is not without complications. These problems can be minimised by ensuring that the ligature is secured correctly, and by selection of the correct device size.

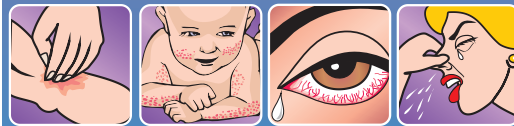1. Healy PJ, Bliss DP, Waldhausen JHT. Necrotizing fasciitis after Plastibell circumcision. *J Pediatr* 1997; 131:459-462.
2. Fraser IA, Allen MJ, Bagshaw PE, Johnstone M. A randomized trial to assess childhood circumcision with the Plastibell device compared to a conventional dissection technique. *Br J Surg* 1981; 68: 593-595.
3. Manji KP. Circumcision of the young infant in a developing country using the Plastibell. *Ann Trop Paediatr* 2000; 20: 101-104.



Are allergies affecting your health?

"One in 10 South Africans are sensitised to the house dust mite and show symptoms of allergy... This makes it the single most common and significant allergen in South Africa today."
- Top Ear, Nose & Throat Surgeon, October 2002

You probably know that almost 30% of all visits to the doctor are to treat allergies or allergic reactions. But did you know that dust mite droppings could be the cause? Top GPs, paediatricians and ENTs agree that dust mite excretions can lead to:



Itchiness Eczema Urticaria Rashes Itchy eyes Conjunctivitis Rhinitis Asthma

Medical research shows that millions of dust mites live in every home no matter how clean it is. They excrete their waste into beds, pillows, carpets, furniture and fluffy toys and even pets.

Scientifically formulated MiteFree:

- 1 combats dust mite allergens,
- 2 neutralises the harmful proteins dust mites excrete and
- 3 disinfects the home.



mite free
DUST MITE SPRAY

MiteFree Dust Mite Spray is non-toxic, non-carcinogenic and fully biodegradable. Approved by the SABS, it is safe to use in all beds, cots and cribs.



www.mitefree.co.za

Available at leading pharmacies. Ask for MiteFree by name.