



CLINICAL IMAGES

Apraclonidine in the diagnosis of Horner's syndrome

A A Moodley, R B Spooner

The use of topical apraclonidine 0.5% in the diagnosis of Horner's syndrome is gaining wide acceptance.¹⁻³ Horner's syndrome characteristically presents with the tetrad of ptosis, miosis, anhidrosis and apparent enophthalmos secondary to a reduced palpebral fissure from upper-lid ptosis and elevation of the lower lid, so-called inverted ptosis. A large spectrum of disorders both central and peripheral from the hypothalamus to the orbit may be implicated in Horner's syndrome. While any of the 1st, 2nd or 3rd-order oculosympathetic neurons may be involved, the co-existence of cerebral, brainstem, spinal cord, brachial plexus, carotid, cavernous sinus or orbital signs aid enormously in localisation of lesions. Still, Horner's syndrome *per se* remains a robust sign and is always ipsilateral to the lesion.

Topical apraclonidine has been shown to have many advantages over the conventional use of topical cocaine 4% in confirming the presence of Horner's syndrome. The lack of availability of cocaine 4% makes it an unpopular choice. Cocaine is a noradrenaline re-uptake inhibitor that results in increased noradrenaline levels at the neuromuscular junction of the normal pupil; hence mydriasis occurs in the normal pupil but not in the noradrenaline-deficient Horner's pupil. Topical cocaine is a weak dilator of the normal pupil, with many documented failures. Being a controlled substance and an illegal recreational drug, patients may show reluctance regarding its use as a test agent. Urine metabolites of cocaine are also present because of systemic absorption.²

Pharmacological confirmation of Horner's syndrome is often needed because of the frequent co-existence of physiological anisocoria and mechanical ptosis, especially in the elderly. In children, the spectrum of causes varies from the benign congenital type to the highly malignant neuroblastoma.⁴ Topical apraclonidine has been shown to supersede cocaine for this purpose as it is readily available and adequately sensitive (87% sensitivity).⁵ Apraclonidine is a weak α_1 -agonist and a strong

α_2 -agonist. Following Horner's syndrome there is up-regulation of α_1 -receptors that increases apraclonidine sensitivity. In response to apraclonidine, the denervation supersensitivity results in pupillary dilatation and lid elevation on the abnormal side but no response or slight miosis on the normal side from α_2 -activity.⁵ The presynaptic α_2 -activity, which inhibits the release of noradrenaline, is negligible in the presence of noradrenaline deficiency in the Horner's pupil.⁵ The effect of apraclonidine is most evident 30 minutes after instillation when the result should be interpreted. Pilocarpine 0.125% used for the testing of Holmes-Adie pupil works on the similar principle of denervation supersensitivity within the oculo-parasympathetic system.

A 75-year-old man experienced a transient ischaemic attack while driving; he suddenly lost focus on the road ahead and the scenery in front of him seemed to expand. He stopped his vehicle and sought help. He had difficulty with reading for the rest of the day but made a full recovery. He had well-controlled hypertension, no diabetes mellitus and no hyperlipidaemia and was a teetotaler. Clinical examination revealed a well person with hypertension, symmetrical carotid pulses and no bruits. He had a right Horner's syndrome and other cranial nerves were intact. There was no pyramidal tract, sensory or cerebellar signs and his gait was also normal. Computed tomography (CT) scan of the brain demonstrated a right caudate nucleus lacunar infarct. Chest radiograph, full blood count, urea and electrolytes, blood glucose, liver function tests and lipid profile were normal. Carotid doppler studies demonstrated normal flow and no stenosis but vertebral doppler studies were suboptimal. Nevertheless, the clinical impression was that of vertebro-basilar ischaemia.

Fig. 1 shows pre- and post-apraclonidine instillation. The relative mydriasis and reversal of ptosis on the abnormal right side following apraclonidine confirm the presence of right Horner's syndrome. The relative miosis induced in the normal pupil is the result of apraclonidine on presynaptic α_2 -receptors. Brainstem infarction was suspected as a cause for the patient's Horner's syndrome.

Topical apraclonidine is useful in confirming the presence of Horner's syndrome. Its mydriatic effect on the abnormal pupil makes for easier interpretation, as seen in Fig. 1. In acute cases false-negative results may be obtained since the effect of apraclonidine is dependent on up-regulation of α_1 -receptors, which takes between 5 and 8 days to develop.³ Therefore apraclonidine is recommended as first-line agent in testing

506

Dr Moodley is a consultant neurologist and Dr Spooner a consultant ophthalmologist at Grey's Hospital, Pietermaritzburg. They run the Neuro-ophthalmology Unit at the hospital, which provides comprehensive patient care and excellent training for their respective registrars.

Corresponding author: A Moodley (anand.moodley@kznhealth.gov.za)

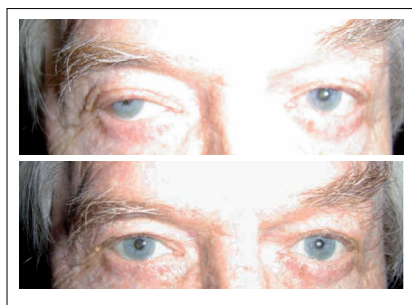


Fig. 1. Before (above) and 30 minutes after apraclonidine.

and if there is no response in the acute setting, cocaine is considered as the alternative.¹

Topical apraclonidine is currently used for reduction of intra-ocular pressure in acute angle closure glaucoma and following YAG laser therapy. Because of the weak α_1 -activity it has been shown to be useful in diagnosing Horner's syndrome regardless of the site of the lesion.

1. Freedman KA, Brown SM. Topical apraclonidine in the diagnosis of suspected Horner syndrome. *J Neuroophthalmol* 2005; 25: 83-85.
2. Kardon R. Are we ready to replace cocaine with apraclonidine in the pharmacologic diagnosis of Horner syndrome? *J Neuroophthalmol* 2005; 25: 69-70.
3. Brown SM. The utility of 0.5% apraclonidine in the diagnosis of Horner syndrome. *Arch Ophthalmol* 2005; 123: 578.
4. Bacal DA, Levy SR. The use of apraclonidine in the diagnosis of Horner syndrome in paediatric patients. *Arch Ophthalmol* 2004; 122: 276-279.
5. Koc F, Kavuncu S, Kansu T, et al. The sensitivity and specificity of 0.5% apraclonidine in the diagnosis of oculosympathetic paresis. *Br J Ophthalmol* 2005; 89: 1442-1444.

DRUG ALERT

Promethazine contraindicated in children under 2 years of age

The Medicines Control Council (MCC) alerts health care professionals to new prescribing information for promethazine.

The package inserts for promethazine-containing products are currently being updated to reflect a contraindication to use in children under the age of 2 years because of the potential for fatal respiratory depression in this age group.

Serious life-threatening cases of respiratory depression, including fatalities, have been reported with promethazine use in paediatric patients under 2 years of age.¹⁻³ Promethazine should therefore not be administered to children under 2 years of age, and with caution to children of 2 years and older, and the lowest effective dose should be used in this group.²

Promethazine is used as an antihistamine, sedative, or anti-emetic. There are several over-the-counter products that contain promethazine. These include antihistamines, combination analgesics/antipyretic paediatric syrups,

and cough and cold preparations. Prescribers and users of these products should check the ingredients and review the revised package insert and patient information leaflet before prescribing or using promethazine-containing products.

Health care professionals are encouraged to report any adverse reactions associated with the use of medicines to the MCC's National Adverse Drug Event Monitoring Centre (NADEMC) by telephone (021 447-1618) or fax (021 448-6181).

National Drug Event Monitoring Centre
Medicines Control Council
Cape Town

1. Sweetman SC, ed. *Martindale: The Complete Drug Reference*. 34th ed. London: Pharmaceutical Press, 2005: 439-440.
2. Starke PR, Weaver J, Badrul A. Comment from FDA. Boxed warning added to promethazine labelling for paediatric use. *N Engl J Med* 2005; 352 (25): 2653.
3. Hickson GB, Altemeier WA, Clayton EW. Should promethazine in liquid form be available without prescription? *Pediatrics* 1990; 86: 221-225 (Abstract).

Roche recalls Viracept due to chemical impurity

Roche, in agreement and co-operation with health authorities (EMA and Swissmedic), is recalling all batches of Viracept powder and tablets in Europe and some other regions of the world. The USA, Canada and Japan are not affected by this recall.

Roche has received several reports that some batches of Viracept 250 mg tablets have a strange odour. A detailed chemical analysis of the affected tablets showed they contain higher than normal levels of methane sulfonic acid ethyl ester. In the interests of patient safety Roche has decided to recall all batches of Viracept tablets and powder currently on the market.

In South Africa, Roche is working closely with the Medicines Control Council in the process of recalling the products.

Roche has also proactively frozen all stock of the powder and tablets at distributor and wholesaler levels, and is in the process of extending this to pharmacy level.

In South Africa it is estimated that less than 200 patients received Virecept therapy in the last year. Patients are requested to contact their doctors to discuss alternative therapies.

For further information contact Vuuyo Piti, Roche Communications Manager, tel. 011 928-8860, email: vuuyo.piti@roche.com