



## CLINICAL IMAGES

## Tuberculosis and phrenic nerve destruction

Johan J Dempers, Juanita Bezuidenhout, Johann W Schneider, Michèle Janse van Rensburg

Phrenic nerve palsy (PNP) is often associated with *Mycobacterium tuberculosis*-related expansile pneumonia, possibly because of nerve entrapment by healing fibrosis.

Mohan and Jayaswal<sup>1</sup> postulated that pressure on the left phrenic nerve by an enlarged hilar lymph node caused unilateral diaphragmatic paralysis in a 6-year-old boy who developed PNP during the course of pulmonary tuberculosis (PTB). Gie *et al.*<sup>2</sup> described 6 childhood cases of PTB complicated by unilateral PNP. The children did not recover on antituberculosis drugs and steroids, or in 1 case, after surgical decompression. Therefore the theory of glandular compression alone does not adequately account for PNP as a complication of PTB. Our case, in which the fate of the phrenic nerve was confirmed, provides strong evidence that destruction of the phrenic nerve by the tuberculous inflammatory process is involved in the pathogenesis of diaphragmatic paralysis, which may influence the clinical management of these children.

### Case report

A 22-month-old girl presented with a lower respiratory tract infection and failure to thrive. There was decreased air entry of the lungs and dullness on percussion over the left hemithorax. The Mantoux test was positive and antituberculous treatment was administered. The enzyme-linked immunosorbent assay (ELISA) test for HIV was negative. Chest radiographs and com-

puted tomography (CT) scans showed expansile pneumonia on the left, total occlusion of the left main bronchus by a left hilar mass, partially occluded right main bronchus (Fig. 1) and elevated left hemidiaphragm. Following bronchoscopy the patient was initially well, but she died later the same day. Postmortem examination showed a malnourished growth-retarded child. Multiple tubercles were present in the lungs, liver and spleen and the entire left lung appeared consolidated. There were enlarged mediastinal lymph nodes and a small straw-coloured pleural effusion on the left. The hilar lymph nodes were matted forming a large mass with central caseous-like necrosis that eroded through the left main bronchus that contained caseous material. This and the scant pulmonary reserve were thought to constitute the cause of death. The left phrenic nerve was seen to enter and leave this necrotising inflammatory mass (Fig. 2). It was easily identified at the periphery of the pericardial tissue (Fig. 3), but disappeared into the granulomatous necrotic mass. Immunostains demonstrated remnants of the phrenic nerve in the granulomatous tissue in the left hilar region (Fig. 4).

### Discussion

PNP is rare in children.<sup>1</sup> Common causes of PNP are surgery for congenital heart lesions,<sup>3-5</sup> traction injury during traumatic delivery<sup>3-5</sup> and as a complication of indwelling subclavian vein catheters in children with renal failure.<sup>6</sup>

Tuberculosis has reached epidemic proportions, with annual worldwide incidence estimated at 8 - 10 million cases and

*Johan Dempers, of the Department of Forensic Medicine and Pathology, Stellenbosch University, is particularly interested in the development of strategies to re-implement the autopsy as a teaching tool and in special dissection techniques in forensic pathology.*

*Juanita Bezuidenhout, a specialist in the National Health Laboratory Services, Tygerberg Coastal Branch/Stellenbosch University, is passionate about postgraduate teaching and sees herself as a jack of all trades in medical education.*

*Johan Schneider, a specialist in the Department of Anatomical Pathology, Stellenbosch University and NHLS Tygerberg, has a keen interest in dermatopathology and the promotion of pathology as a core component of patient care.*

*Michèle Janse van Rensburg recently completed her community service commitments and has accepted a post as registrar in forensic pathology at Tygerberg Academic Hospital.*

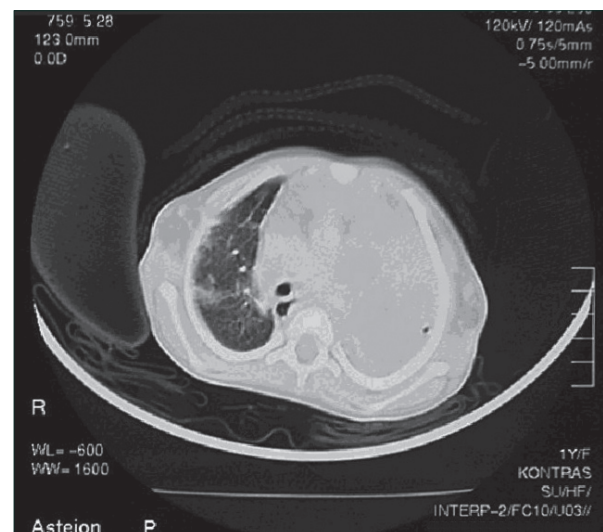


Fig. 1. CT scan of the chest showing consolidation of the left lung and prominent hilar lymphadenopathy.

Corresponding author: J J Dempers (jd2@sun.ac.za)

August 2007, Vol. 97, No. 8 SAMJ

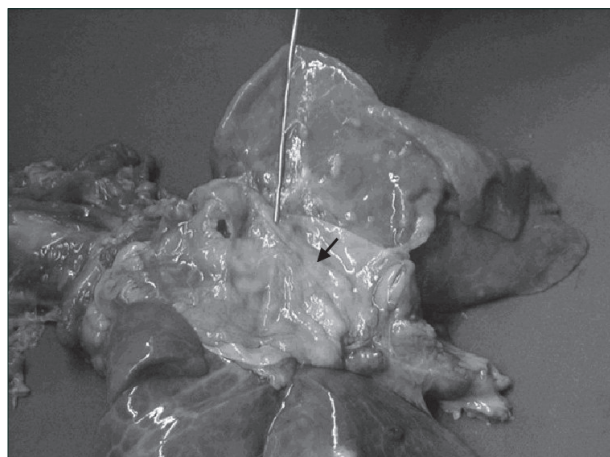


Fig. 2. Thoracic pluck with heart removed. The left phrenic nerve is indicated by the pointer on the superior aspect of the pericardium. It disappears into a focus of granulomatous inflammation on the pericardial surface (arrow). The suspected course of the phrenic nerve in this area was inked before dissection (not shown).

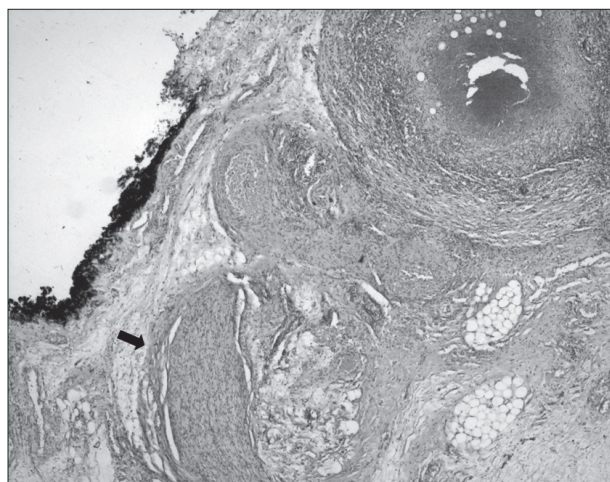


Fig. 3. Inked surface of the pericardium with clearly visible phrenic nerve (arrow).



Fig. 4. Positive neurofilament (NF) immunohistochemical staining of destroyed phrenic nerve in granulomatous pericardial inflammation (demarcated by arrows).

mortality at 2 - 3 million people.<sup>7</sup> The vast majority of these cases occur in the developing world where rare manifestations of tuberculosis are also more common. PTB rarely causes PNP, but few cases have been described in the English literature.<sup>1,2</sup>

Young children are unable to compensate effectively for a paralysed hemi-diaphragm because of their greater reliance on the diaphragm for ventilation in a more horizontally arranged ribcage with underdeveloped intercostal muscles,<sup>3,5</sup> a relatively mobile mediastinum,<sup>3</sup> a more compliant chest wall owing to incomplete ossification,<sup>5</sup> and narrow, easily obstructed bronchi.<sup>3</sup> PNP causes a mediastinal shift and paradoxical movement of the diaphragm, resulting in alveolar hypoventilation and atelectasis on the affected side and more pronounced when supine.<sup>3,5</sup> Clinically, these changes may manifest as respiratory distress,<sup>3,4,6</sup> recurrent pneumonia<sup>3,6</sup> or ventilator dependence.<sup>3,4</sup> The consequences of PNP in young children are therefore dire.

Use of antituberculosis drugs and steroids in the treatment of PNP in tuberculous hilar lymphadenopathy is based on the postulation that phrenic nerve compression causing temporary PNP should improve once the cause of the compression is removed. Langer *et al.*<sup>3</sup> described a series of 23 paediatric patients who underwent surgical diaphragmatic plication for symptomatic PNP. Postoperative complications were the exception. They concluded that plication of the diaphragm is safe and effective. Another study concluded a favourable long-term outcome in children followed up for 1 - 7 years.<sup>8</sup> Numerous authors currently favour the procedure as the definitive treatment for symptomatic PNP without prospect of spontaneous improvement.<sup>3</sup> The surgical procedure aims to decrease lung compression, stabilise the mediastinum and strengthen the actions of the intercostal and abdominal muscles. Diaphragmatic recruitment is more effective and there is a significant improvement in the patients' respiratory function postoperatively.<sup>4</sup>

Our findings indicate that in addition to the proposed compression of the phrenic nerve, it may also be permanently damaged by the granulomatous inflammation, in which case medical treatment alone is unlikely to improve the diaphragmatic paralysis. Other authors support this view.<sup>1,2</sup> Children with symptomatic PNP as a complication of tuberculosis should therefore be considered for surgery, since the prospect of spontaneous recovery of the phrenic nerve paralysis is poor.

1. Mohan B, Jayaswal SN. Unilateral diaphragmatic paralysis due to tuberculous hilar adenitis. *Indian J Pediatr* 1985; 22: 468-470.
2. Gie RP, Goussard P, Kling S, Schaaf HS, Beyers N. Unusual forms of intrathoracic tuberculosis in children and their management. *Paediatric Respiratory Reviews* 2004; 5: Suppl A, S139-S141.
3. Langer JC, Filler RM, Coles J, Edmonds JF. Plication of the diaphragm for infants and young children with phrenic nerve palsy. *J Pediatr Surg* 1988; 23: 749-751.
4. Simansky DA, Paley M, Refaely Y, Yellin A. Diaphragm plication following phrenic nerve injury: a comparison of paediatric and adult patients. *Thorax* 2002; 57: 613-616.
5. Raine J, Samuels MP, Mok Q, Shinebourne EA, Southall DP. Negative extrathoracic pressure ventilation for phrenic nerve palsy after paediatric cardiac surgery. *Br Heart J* 1992; 67: 308-311.
6. Aggarwal S, Hari P, Bagga A, Mehta SN. Phrenic nerve palsy: a rare complication of indwelling subclavian vein catheter. *Pediatr Nephrol* 2000; 14: 203-204.
7. Coovadia HM. Tuberculosis. In: Coovadia HM, Wittenberg DF, eds. *Paediatrics and Child Health*. 4th ed. Cape Town: Oxford University Press, 1998: 321-340.
8. Stone KS, Brown JW, Canal DF, King H. Long-term fate of the diaphragm surgically plicated during infancy and early childhood. *Ann Thorac Surg* 1987; 44: 62-65.