CLINICAL PRACTICE

The complexity of HIV vasculopathy

Alan Stanley, Sally Candy, Candyce Levin, Jeannine M Heckmann

We present a case and discuss stroke related to human immunodeficiency virus (HIV) infection and the difficulties of reaching a firm diagnosis of the cause of the aneurysmal vasculopathy. In the absence of a clear aetiology we suggest looking for varicella zoster virus (VZV) replication in the cerebrospinal fluid (CSF) by polymerase chain reaction (PCR) and treating with intravenous acyclovir, aiming for HIV control with appropriate antiretroviral therapy and providing suitable antiplatelet agents. If there is a high index of suspicion of VZV, therapy with acyclovir may be prudent even if the CSF PCR is negative (as may occur after the first 2 weeks of reactivation of infection). Determination of a VZV plasma:CSF IgG ratio is not readily available and would only provide surrogate support for a previous VZV infection in the central nervous system compartment.

S Afr Med J 2012;102(6):474-476.

Diffuse intracranial fusiform aneurysmal vasculopathy has been described in association with human immunodeficiency virus (HIV) infection, although much more frequently in children than in adults. This usually presents as either ischaemic or haemorrhagic stroke or subarachnoid haemorrhage, but has also been found incidentally. Neither the aetiology, nor the treatment of these strokes, is clear. We present a case in which the chronological events may shed some light on the pathogenesis of HIV-associated vasculopathy and outline the current understanding of this complex problem.

Case report

A 22-year-old woman presented with an acute stroke manifesting with left hemiparesis and hemineglect. She was HIV-positive with a CD4 count of 210/µl and receiving second-line antiretroviral therapy (ART) consisting of tenofovir, lamivudine and Alluvia. She had a 6 pack year smoking history but had not used any recreational drugs. She had no other vascular risk factors for stroke.

She had first been seen 13 months earlier in June 2010 when she was diagnosed with cytomegalovirus (CMV) retinitis and found to be HIV infected. A vitreous tap was performed and a polymerase chain reaction (PCR) was positive for CMV but negative for varicella zoster virus (VZV), herpes simplex virus (HSV)-1 and -2, *Toxoplasma gondii* and *Mycobacterium tuberculosis*. Her CD4 count was 76/µl. She was treated with intravitreous gancyclovir, and ART (lamivudine, tenofovir and nevirapine) was started in November 2010. A month later a contrast-enhanced computed tomography (CT) brain scan was normal apart from generalised cortical atrophy (Fig. 1A). Her CD4 count had increased to 99/µl, but by January 2011 had deteriorated to 20/µl, suggesting non-adherence to therapy. Despite appropriate management her vision continued to deteriorate. A repeat vitreous tap in April 2011 showed a positive PCR for VZV in addition to CMV and she received 2 weeks of intravenous (IV) acyclovir. In July 2011 her CD4 count was 29/µl and viral load was 2 037 280 RNA cps/ml. She admitted non-adherence to ART, possibly because of poor vision. Having failed her first ART regimen, she was switched to second-line therapy (detailed above).

Three months later she presented with right partial anterior circulation stroke. A CT brain scan confirmed a right middle cerebral artery territory infarct (not shown). In addition, a CT cerebral angiogram demonstrated diffuse fusiform aneurysmal dilatation of all vessels of the circle of Willis (Figs 1B and C). A subsequent magnetic resonance imaging (MRI) scan confirmed these abnormalities and demonstrated additional infarcts in the left posterior globus pallidus and right corpus striatum (Fig. 1D). The cerebrospinal fluid (CSF) showed an elevated protein (0.98 g/l; normal = 0.15 - 0.45), normal glucose (2.6 mmol/l; serum glucose 5.1 mmol/l) with 10 lymphocytes, 0 polymorphonuclear cells and 5 erythrocytes. The CSF IgG index was elevated at 1 (normal <0.7) as was the CSF IgG synthesis rate (>100 mg/24 h; normal ≤3.3). The fluorescent treponemal antigen (FTA), cryptococcal latex agglutination test (CLAT) and Gram stain and culture were all negative. PCR for VZV, HSV-1 and -2 and CMV were negative. She was initially treated with empirical IV acyclovir but this was discontinued when the PCR for VZV in the CSF proved negative. She was started on aspirin and made a significant recovery from the stroke although she remained functionally blind as a consequence of CMV retinitis.

Discussion

Fusiform aneurysmal vasculopathy has been reported in HIV-infected subjects with stroke although the aetiology remains uncertain.[1] We present a patient with HIV/AIDS who was profoundly immune-compromised when she presented with CMV retinitis. At that time, a contrast-enhanced CT scan showed that her brain (and medium-sized cerebral vessels) were normal, apart from HIV-associated cortical atrophy. Subsequently, she developed evidence of VZV (re)activation/replication albeit in the vitreous of the eye, and a few months later presented with relatively widespread intracranial fusiform aneurysmal vasculopathy complicated by cerebral infarcts. The cause of HIV-associated vasculopathy is contentious, but the most frequent aetiological considerations are that it is due to varicella zoster or to HIV itself. Other causes, such as syphilis, were excluded in this patient and CMV has not been associated with aneurysmal vasculitis.[2]

Alan Stanley is a senior lecturer and consultant in the Department of Medicine, University of Cape Town, with a research interest in HIV-related cerebrovascular disease. Sally Candy is a consultant neuroradiologist, in the Department of Radiology, University of Cape Town and Groote Schuur Hospital, Cape Town. Candyce Levin is a medical intern in the Department of Medicine, Victoria Hospital, Cape Town. Jeannine Heckmann is Associate Professor of Neurology, Department of Medicine, University of Cape Town and Groote Schuur Hospital, with research interests in neuromuscular disease particularly myasthenia gravis and HIV-associated neuromuscular disease.

Corresponding author: *A Stanley (alan.stanley@uct.ac.za)*

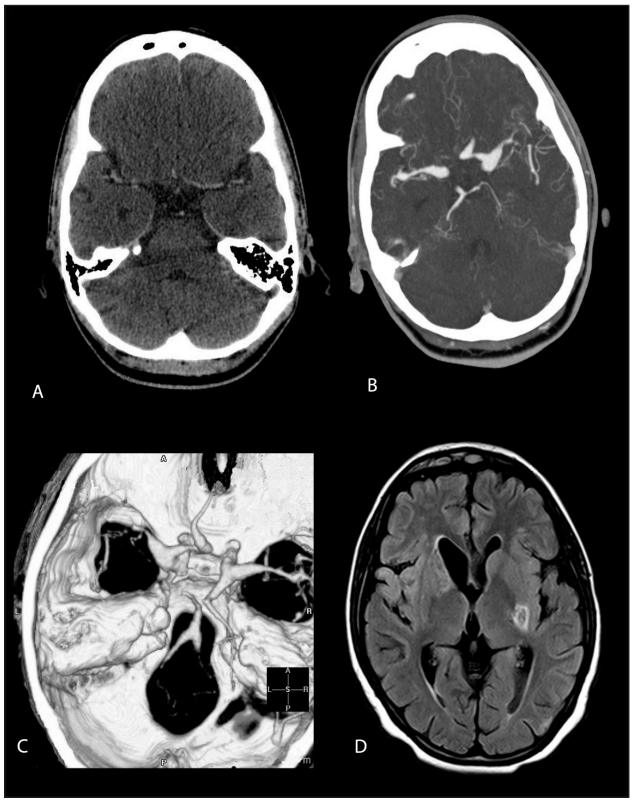

Fig. 1. (A) Contrast-enhanced CT brain scan (3/12/2010) at the level of the circle of Willis showing bilateral normal calibre middle cerebral arteries. (B) CT cerebral angiogram (CTA) source image 3D MIP (5/10/2011) demonstrating fusiform aneurysmal dilatation of both right and left middle cerebral arteries and left anterior cerebral artery. (C) Volume-rendered 3D image of the CTA (5/10/2011) showing diffuse fusiform aneurysmal vasculopathy of the circle of Willis, vertebral, basilar and left posterior communicating arteries. (D) MRI FLAIR (TE 114, TR10 000) demonstrating increased signal in the right corpus striatum (with ex vacuo *dilatation), insular- and peri-sylvian cortices as well as left posterior globus pallidus.*

HIV-associated intracranial fusiform aneurysmal vasculopathy was first described in children in the 1980s and over the last decade has been increasingly reported in adult patients (n=19).[1] Strokes usually present as a partial anterior circulation infarction, but subarachnoid haemorrhages as well as clinical presentations of seizures and encephalopathy have been reported.[1] Patients typically have CD4 counts of <200/µl although cases with higher CD4 counts are described. Neuro-imaging shows fusiform dilatation and stenosis of multiple intracranial arteries.[1] Relatively few cases have come to autopsy, but in those where histological examination of the cerebral vasculature was possible, there was fragmentation of the internal elastic lamina with medial and adventitial fibrosis. Some cases have also shown intimal hypertrophy.[1,2] These findings are similar to those described for VZV and most reports have not systematically excluded VZV.[3,4] When presence of VZV was investigated it mainly involved measuring active viral replication via CSF PCR, which, as discussed below, may not always be relevant. Nevertheless, there are several cases where VZV antigen was not histologically detected and where HIV was identified in the vessel wall by immune-histochemistry (anti-gp41) or PCR.[1]

Further support for HIV as the direct cause for intracranial vasculopathy comes from the fact that HIV causes an extracranial and peripheral large-vessel vasculopathy, a finding that is extremely rare with VZV.[2] This large-vessel vasculopathy shows similar histology to the intracranial variant described above. Interestingly, vasculopathy is also observed in simian immunodeficiency virus-infected rhesus monkeys and in a mouse model of HIV vasculopathy using a defective HIV pro-virus.[5] The transgenic mice develop a diffuse vasculopathy with intimal hypertrophy, primarily a result of smooth-muscle proliferation, disruption of the elastic lamina and fibrosis of the media and adventitia – findings similar to those seen in HIV-associated vasculopathy.

Stroke related to recent VZV infection is also well described with more than 70 cases reported among children. This association has also been observed in adults ,with the largest series containing 30 patients. In addition there are 8 separately described cases of VZV with an associated aneurysmal vasculopathy.[4] Ischaemic or haemorrhagic strokes, lacunar infarcts and even multiple strokes in different arterial territories have been described with or without associated HIV infection. Forty per cent of the paediatric HIV-infected cases had no clinical evidence of VZV infection at the time of stroke, which is not surprising if the VZV vessel destruction occurred asymptomatically previously. It has been suggested that VZV-associated vasculopathy is highly likely if the clinical features are accompanied by evidence of current CSF VZV infection (positive VZV PCR) or previous evidence of VZV replication within the central nervous system (CNS) compartment (increased CSF/serum VZV IgG ratio).[4] The retina is an extension of the CNS, and importantly our case had evidence of VZV replication in the vitreous, suggesting that the CNS was exposed to the VZV infection.

VZV vasculopathy involves both large and small intracranial vessels. The most frequent angiographic abnormalities are segmental constriction with poststenotic dilatation. Fusiform aneurysmal dilatation is less common.[3] Recently Nagel *et al.*[6] described 3 histologically confirmed cases of stroke due to varicella vasculopathy. These were both early (4 weeks after VZV infection) and late VZV (48 weeks after infection) vascular presentations and showed surprisingly widespread involvement of cerebral vasculature. Significantly, in this series, VZV antigen was detected in the adventitia of the early biopsy specimen (before acyclovir) and in the media and intima of the later case (after treatment of acyclovir), suggesting that after VZV reaches the vessel wall via axonal spread, it spreads transmurally through vessel walls.

The persistence of VZV DNA in the vessel wall after a course of IV acyclovir as found in a case at postmortem is of concern.[4] Some cases have been treated with empirical oral valacyclovir following a course of IV acyclovir.[4] However, most cases of VZV vasculopathy are reported to stabilise after treatment.

The difficulty for the clinician lies in distinguishing HIV vasculopathy from VZV vasculopathy, and in determining whether aneurysmal vasculopathy represents a specific, possibly latent, VZV vasculopathy in HIV-infected hosts. Although the development of aneurysmal vasculopathy in our patient was temporally associated with VZV reactivation in the CNS, HIV replication was also uncontrolled. It is possible that an HIV-infected individual with VZV vasculopathy is at greater risk of developing the aneurysmal form of vasculopathy. An additional intriguing feature of our case is that she presented with stroke at a time when systemic immune reconstitution had occurred.

In conclusion, this case highlights some of the difficulties associated with identifying the cause of aneurysmal vasculopathy in an HIV-infected individual. In the absence of a clear aetiology we suggest looking for VZV replication in the CSF by PCR and treating with IV acyclovir, aiming for HIV control with appropriate ART and providing suitable antiplatelet agents. If there is a high index of suspicion of VZV, therapy with acyclovir may be prudent even

if the CSF PCR is negative (as may occur after the first 2 weeks of reactivation of infection). It is worth noting that determination of a VZV plasma:CSF IgG ratio is not readily available and would only provide surrogate support for a previous VZV infection in the CNS compartment.

1. Goldstein DA, Timpone J, Cupps TR. HIV-associated intracranial aneurysmal vasculopathy in adults. J Rheumatol 2010;37(2):226-233. [http://dx.doi.org/10.3899/jrheum.090643]
2. Chetty R. Vasculitides associated with HIV infection. J Clin Pathol 2001;54(4):275-278. [http://dx.doi.org/10.1136/jcp.54.4.275]
3. Bhayani N, Ranade P, Clark NM, McGuinn M. Varicella-zoster virus and cerebral aneurysm: case report and review of the literature. Clin Infect Dis 2008;47(1):e1-3. [http://dx.doi.org/10.1086/588842]
4. Nagel MA, Cohrs RJ, Mahalingam R, et al. The varicella zoster virus vasculopathies: clinical, CSF, imaging, and virologic features. Neurology 2008;70(11):853-860. [http://dx.doi.org/10.1212/01.wnl.0000304747.38502.e8]
5. Tinkle BT, Ngo L, Luciw PA, Maciag T, Jay G. Human immunodeficiency virus-associated vasculopathy in transgenic mice. J Virol 1997;71(6):4809-4814.
6. Nagel MA, Traktinskiy I, Azarkh Y, et al. Varicella zoster virus vasculopathy: analysis of virus-infected arteries. Neurology 2011;77(4):364-370. [http://dx.doi.org/10.1212/WNL.0b013e3182267bfa]

Accepted 17 January 2012.