

## CLINICAL PRACTICE

## Herpetic ulcer of the eyelids in an immunocompromised patient

Nagib du Toit, Junet van der Merwe

A 24-year-old black female (HIV-positive) was referred to our clinic with a 4-week history of an ulcerative lesion of the right upper and lower eyelids. She was on treatment for pulmonary tuberculosis and had been admitted to a secondary level hospital. She had no other ocular symptoms or signs. A tissue biopsy of the lesion revealed multinucleate squamous cells with ground glass viral nuclear inclusion bodies, indicative of herpes simplex virus (HSV)

infection. The ulcer healed with oral and topical acyclovir therapy, confirming a herpetic origin. There is only one other reported case of this type of ulcerative eyelid lesion caused by HSV; the patient in this case was also immunocompromised.

*S Afr Med J* 2012;102(6):472-473.

Opportunistic infections and uncommon neoplasms are known to occur in patients with the acquired immunodeficiency syndrome (AIDS). The most common eyelid manifestations are Kaposi sarcoma, *Molluscum contagiosum*, *Verruca vulgaris*, and non-Hodgkin lymphoma.<sup>1</sup> Herpes simplex virus (HSV) infection needs to be considered in the differential diagnosis in human immunodeficiency virus (HIV)-positive patients with an ulcerative lesion of the eyelids. The ulcer may mimic a neoplastic lesion in morphology, but the acute nature of onset and patient background should alert the clinician to an infective process. The diagnosis can be confirmed by biopsy and histology. Initiation of appropriate, early treatment should have good results, as evident from this report.

### Case report

A 24-year-old unemployed female presented to the ophthalmology service with a one-month history of a gradually enlarging, ulcerative lesion of the right lower and upper eyelids in the area of the medial canthus. The patient history was that of being HIV-positive with a CD4 cell count of 49. She had not been started on antiretroviral treatment. She was known to have pulmonary tuberculosis (TB) and was on treatment for TB about 2 weeks prior to presentation. She initially presented to a secondary level hospital with a mildly-red, irritated right eye and had been treated with chloramphenicol eye ointment. After 2 weeks of treatment, with the lesion extending to the eyelids and having developed a slight mucopurulent discharge, the treatment was changed to dexamethasone eye drops at the secondary hospital. After a further 2 weeks with no improvement, the patient was referred to the ophthalmology service. It was thought that the lesion might be related to the patient's pulmonary TB. The lesion was ulcerative in morphology and had a reddish-yellow granulomatous appearance, with slough in the base and rolled overhanging edges (Fig. 1). The patient did not have any other ocular symptoms or signs.

Incisional tissue biopsies were taken at various sites, including the margin of the lesion, and some surrounding normal tissue. Histology

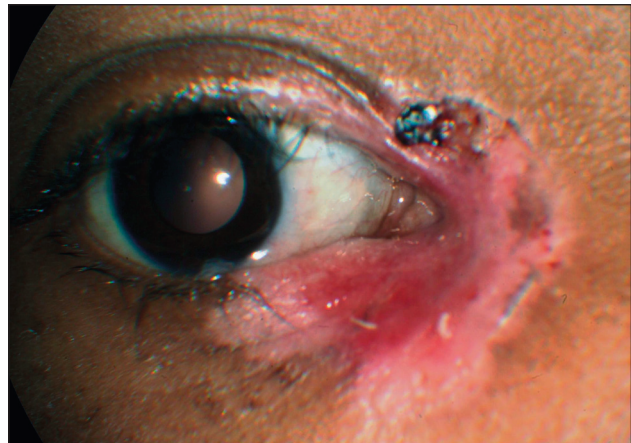


Fig. 1. Medial canthal area showing ulcerated lesion.

showed multinucleate squamous cells with ground-glass viral nuclear inclusion bodies, indicative of HSV infection. No acid-fast bacilli were identified on Ziehl-Neelsen staining. There were no granulomas present and no dysplasia of the epithelium. The patient was treated with oral acyclovir (800 mg 5 times per day) for 1 week and topical acyclovir ointment (to be used until the lesion healed). There was a marked improvement, with the ulcer almost completely healed after only 1 week of treatment. The patient was advised to continue treatment, but did not return for follow-up.

### Discussion

HSV infection of the eye can vary from mild blepharitis to sight-threatening chorioretinitis. Primary infection of the eye is usually subclinical but reactivation of a latent infection can lead to recurrent disease. HSV-1 and HSV-2 infections are known to take atypical forms and persist longer in immunocompromised patients. In this situation, they tend to ulcerate early and may appear as chronic, enlarging necrotic lesions. There are reports of similar lesions presenting on the ear, nose, mouth, neck, legs, back, and genital region in immunocompromised patients.<sup>1</sup>

A similar case was reported by Sturm *et al.* in 2006;<sup>1</sup> the patient had an ulcerated lesion of the eyelid which had been present for 2 months and 'mimicked a malignant lesion'. The diagnosis was confirmed by biopsy and the patient responded to famciclovir treatment.

Ophthalmic infections known to occur with HSV include blepharoconjunctivitis, keratouveitis, acquired ankyloblepharon, and membranous tarsal plaque.<sup>1</sup> There have also been a few published reports of various unusual ophthalmic presentations of herpetic

Nagib du Toit is a consultant ophthalmic surgeon and senior lecturer, and Junet van der Merwe is a senior registrar, in the Division of Ophthalmology, Department of Surgery, Groote Schuur Hospital and University of Cape Town.

Corresponding author: N du Toit (nagib.dutoit@uct.ac.za)

infection: recurrent HSV eyelid infection,<sup>2</sup> herpetic meibomianitis,<sup>3</sup> herpetic-associated refractory (to corticosteroids) pemphigus vulgaris involving the eyelids,<sup>4</sup> as well as other lesions simulating neoplasia in the genital and peri-anal areas.<sup>5</sup> The patients were HIV-positive in many of these reported cases.

In conclusion, this case illustrates a rare clinical presentation of ocular herpes – one of the many manifestations of herpetic infection. Awareness of these unusual presentations in the immunocompromised needs to be created for correct diagnoses and prompt, effective treatment for HSV to achieve good outcomes.

1. Sturm JM, Levine MR, Singh A, et al. Herpetic lesion mimicking lower eyelid malignancy. *Ophthalmol Plast Reconstr Surg* 2006;22(2):147-148.
2. Milazzo L, Trovati S, Pedenovi S, et al. Recurrent herpes simplex virus (HSV) eyelid infection in an HIV-1 infected patient. *Infection* 2007;35(5):393-394.
3. Singh MP, Sharma A, Ratho RK. Herpetic meibomianitis: an unusual case report. *Southeast Asian J Trop Med Public Health* 2007;38(3):466-468.
4. Brandão ML, Fernandes NC, Batista DP, Santos N. Refractory pemphigus vulgaris associated with herpes infection: case report and review. *Rev Inst Med Trop Sao Paulo* 2011;53(2):113-117.
5. Mosunjac M, Park J, Wang W, et al. Genital and perianal herpes simplex simulating neoplasia in patients with AIDS. *AIDS Patient Care STDS* 2009;23(3):153-158.

*Accepted 31 January 2012.*