

CLINICAL IMAGES

Embolic stroke from common carotid pseudo-aneurysm

Anand Odhav Naranbhai, Douglas Wilson, Andrew Michowicz

A 52-year-old man presented with signs of a right middle cerebral artery stroke. A large pulsatile mass was noted at the right base of his neck, together with an overlying scar which the patient reported as being due to a stab wound sustained 22 years ago (Fig. 1). A computed tomography (CT) scan of the brain showed an infarct in the area of the right middle cerebral artery (Fig. 2). Computed tomographic angiography revealed a pseudo-aneurysm of the right common carotid artery at its origin with extensive surrounding thrombus (Fig. 3), as well as paucity of branches of the right middle cerebral artery (Fig. 4). Definitive management of the pseudo-aneurysm was achieved by vascular surgical intervention.

The authors declare that they have no conflicts of interest.

With thanks to L Moodley and K Daji, Department of Radiology, Edendale Hospital, and to Jackpersad & Partners, Specialist Radiologists.

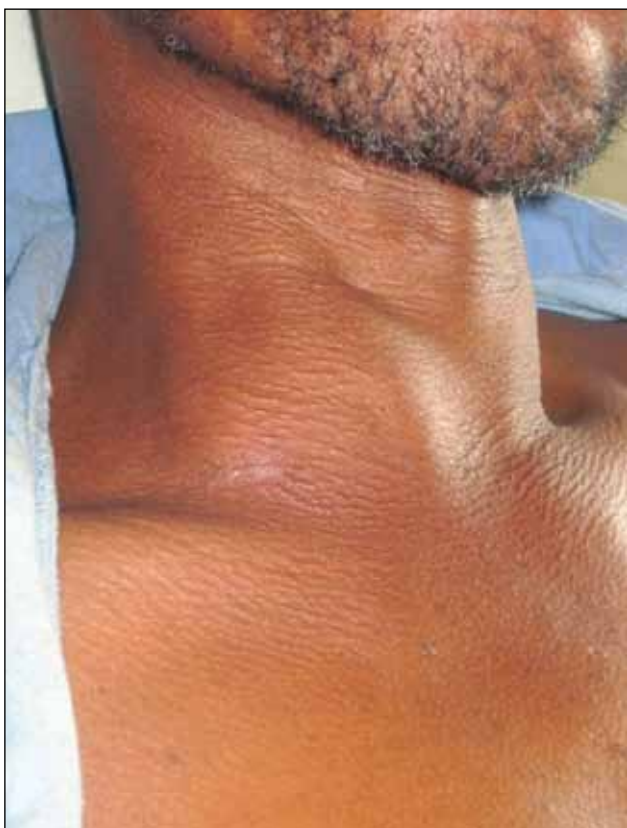

Fig. 1. Photograph showing the patient's large right-sided neck mass.

A O Naranbhai is a 4th-year medical student at the Nelson R Mandela School of Medicine, University of KwaZulu-Natal. A Michowicz (Specialist) and D Wilson (Head of Department) are in the Department of Internal Medicine at Edendale Hospital in KwaZulu-Natal.

Corresponding author: A O Naranbhai (anaranbhai@gmail.com)

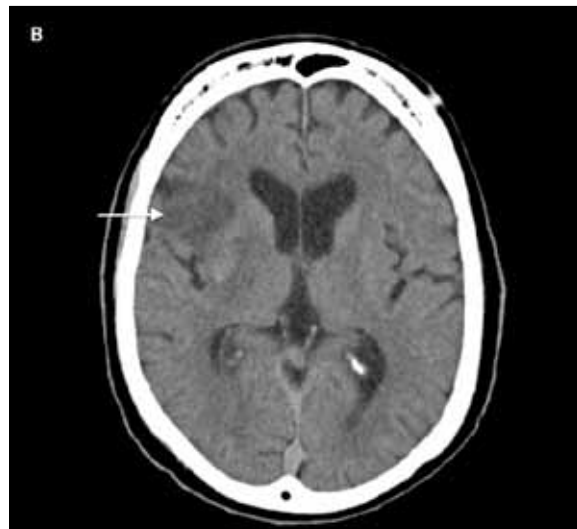

Fig. 2. CT scan of the brain showing infarction in the left temporal region.

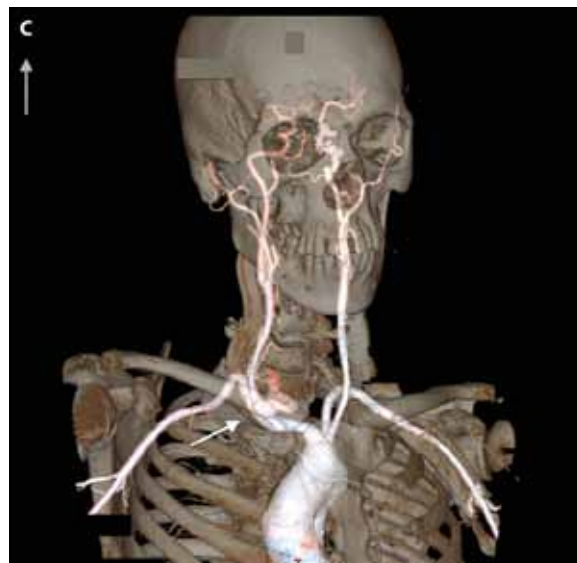


Fig. 3. 3-D reconstruction of vasculature showing a pseudo-aneurysm of the right common carotid artery.

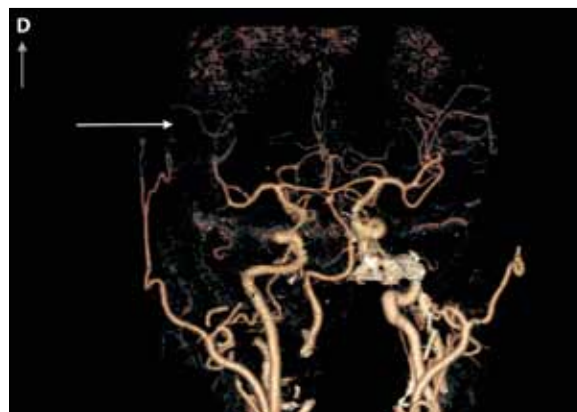


Fig. 4. 3-D reconstruction of cerebral vasculature showing paucity of branches of the right middle cerebral artery.