



## CLINICAL IMAGES

### Iatrogenic pneumatosis intestinalis and pneumatosis hepatis

S W Bickler, A Alexander, R D Pitcher, N Wieselthaler, H Rode

A term male fetus with meconium-stained liquor was delivered at a peripheral hospital. He developed abdominal distension and bile-stained vomiting shortly after birth. Meconium ingestion was suspected. Gastric lavage was attempted using inappropriately high volumes and concentrations of sodium bicarbonate in this newborn with undiagnosed jejunal atresia. Subsequent abdominal radiographs documented the presence of the jejunal atresia and pneumatosis intestinalis (PI), together with air in both the porta hepatis and liver parenchyma (Figs 1 - 3). The latter features were interpreted as representing necrotising enterocolitis. The child was transferred to Red Cross Children's Hospital, Cape Town, for corrective surgery. At operation, type 1 jejunal atresia was confirmed, but the bowel showed no features of enterocolitis. The patient made an uneventful postoperative recovery.

The rapid evolution and resolution of the PI suggests that it was iatrogenic, caused by high intraluminal pressures, precipitated by liberation of carbon dioxide when 75 ml of an 8.5% sodium bicarbonate solution combined with gastric hydrochloric acid.

#### Discussion

The term pneumatosis is used to reflect the presence of gas in an abnormal location in the body.<sup>1</sup>

PI refers to gas collections within the bowel wall. As a pathological entity this was first recognised in the 18th century and in adults it has been described in at least 50 different clinical settings, with widely disparate prognoses.

*Stephen Bickler is Associate Professor of Surgery and Paediatrics at the University of California San Diego. He was a visiting Consultant Paediatric Surgeon at Red Cross Children's Hospital from May to August 2004.*

*Angus Alexander is a Senior Registrar in Paediatric Surgery at Red Cross Children's Hospital, Cape Town*

*Richard Pitcher and Nicky Wieselthaler are Consultant Radiologists at Red Cross Hospital.*

*Heinz Rode, recently retired, was Charles F M Saint Professor of Paediatric Surgery at the University of Cape Town at the time of writing.*

Corresponding author: R Pitcher (pitcher@iafrica.com)

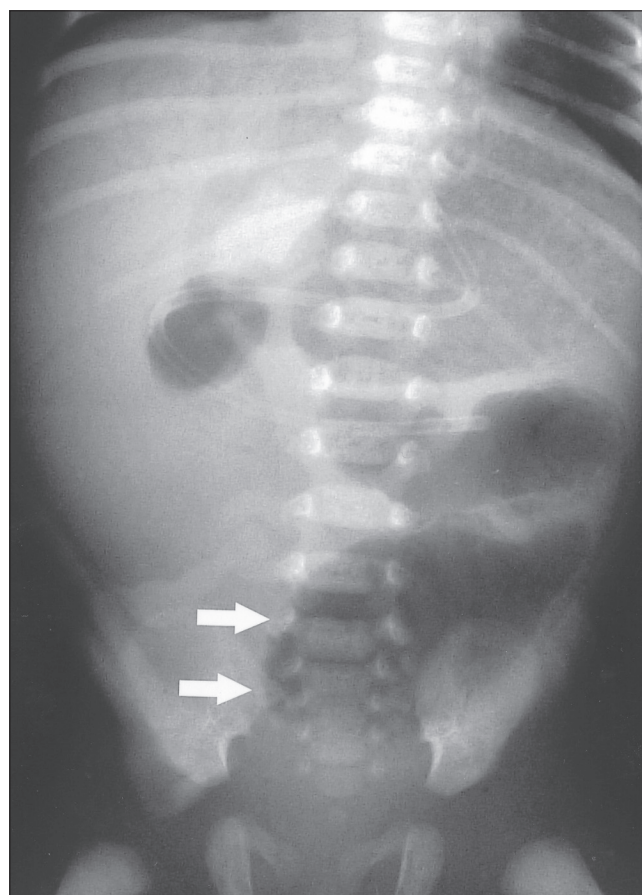


Fig. 1. Admission supine abdominal radiograph, showing a short segment of grossly distended proximal small bowel (arrows) and no distal bowel gas. Features are consistent with high jejunal atresia.

As a radiological sign it can indicate life-threatening bowel ischaemia, necrosis or sepsis but may be a relatively innocuous accompaniment of peptic ulcer disease, intestinal obstruction or obstructive airways disease. It has been seen in association with cancer chemotherapy, post-transplant immunosuppression, high-dose corticosteroids, graft-versus-host disease and more recently in AIDS sufferers. It has also been documented after endoscopy. As with all radiological findings it must be interpreted in its clinical context.<sup>2</sup>

In the premature infant the presence of PI is considered pathognomonic of necrotising enterocolitis and has been documented in up to 85% of such cases.<sup>3</sup> The pathogenesis has not been conclusively demonstrated, with 'mechanical' and

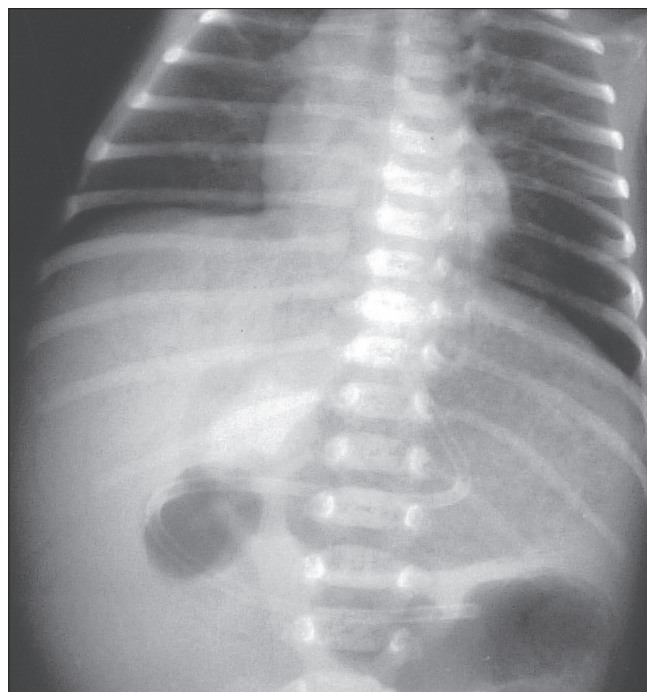


Fig. 2. Magnified view of the distended proximal jejunum, demonstrating loculations of gas within the bowel wall (arrows), representing pneumatosis intestinalis.

'bacterial' hypotheses in contention. The former postulates that gas dissects into the bowel wall from the intestinal lumen while the latter supports gas-forming bacilli entering the submucosa via mucosal rents.

The association of necrotising enterocolitis with air in the portal vein was first documented 50 years ago<sup>4</sup> and is a result of bowel wall gas embolising into the portal venous system. It is accepted as indicating extensive bowel gangrene and has a mortality rate approximating 70%.

Portal venous gas must be differentiated, where possible, from air in biliary tree. Pneumobilia is well recognised in adults in the context of gallstone ileus and after endoscopy. It has also been documented where proximal small-bowel obstruction co-exists with an incompetent sphincter of Oddi.<sup>5</sup> Radiological texts classically differentiate biliary from portal venous gas according to location. Air in portal venous radicals assumes a peripheral, subcapsular location within the liver

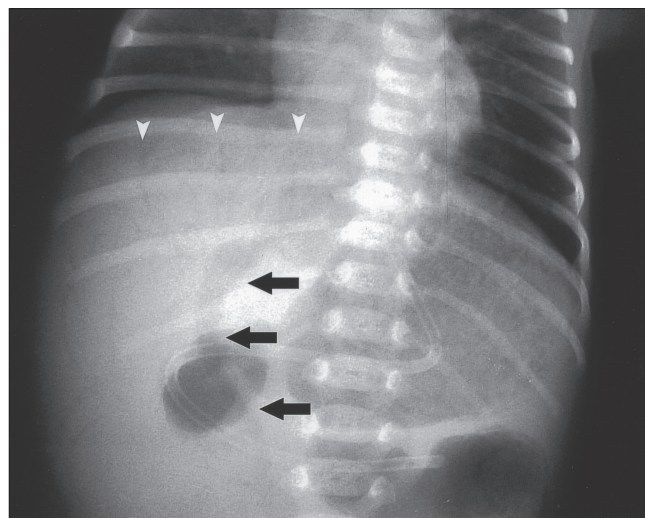


Fig. 3. Localised view of the right upper quadrant of the abdomen, demonstrating gas within a tubular structure in the region of the porta hepatis (black arrows) and gas in small tubular structures in a subcapsular position within the liver parenchyma (white arrow heads).

parenchyma, reflecting the direction of portal venous flow, while air in the biliary tree will have a more central location in the porta hepatis as a consequence of hepatofugal bile flow. However, it is not always possible to make the distinction on radiological criteria alone and the clinical context is again important.

The identification of air in both the porta hepatis and in a subcapsular position in the liver parenchyma (Fig. 3) represents a clinical conundrum. Is it in the portal vein or biliary tree? In this case cogent arguments can be presented for its being in both, given the presence of PI in the face of markedly distended, obstructed proximal small bowel.

Faced with this clinical dilemma, we suggest a new term, pneumatosis hepatitis, encompassing both possibilities!

1. Pear LB. Pneumatosis intestinalis: A review. *Radiology* 1998; 207: 13-19.
2. Heng Y, Schuffler MD, Haggitt RC, Rohrmann CA. Pneumatosis intestinalis: A review. *Am J Gastroenterol* 1995; 90: 1747-1758.
3. Berdon W, Grossman H, Baker D, et al. Necrotising enterocolitis in the premature infant. *Radiology* 1964; 83: 879-887.
4. Wolfe JN, Evans WA. Gas in portal veins of liver in infants: roentgenographic demonstration with post mortem anatomical correlation. *Am J Roentgenol* 1955; 74: 486-489.
5. Bautista JL, Budhreja MD, Barcia TD, Shankel SW. Pneumobilia associated with small bowel obstruction. *JAMA* 1988; 260: 1930-1931.