



This case was challenging because of the long duration, presence of constitutional symptoms, recent ingestion of traditional medicament, shifting dullness and dullness in the flanks on clinical examination, previous non-significant rectal biopsy, ascites revealed on ultrasound examination, and unhelpful laboratory investigations.

1. De Giorgio R, Knowles CH. Acute colonic pseudo-obstruction. *Br J Surg* 2009; 96(3): 229-239.
2. Antonucci A, Fronzoni L, Cogliandro L, et al. Chronic intestinal pseudo-obstruction. *World J Gastroenterol* 2008; 14(19): 2953-2961.
3. Isaacson C, Wainwright HC, Hamilton DG, et al. Hollow visceral myopathy in black South Africans. A report of 14 cases. *S Afr Med J* 1985; 67(25): 1015-1017.
4. Ghavamian R, Wilcox DT, Duffy PG, et al. The urological manifestations of hollow visceral myopathy in children. *J Urol* 1997; 158: 1286-1290.
5. Jones SC, Dixon MF, Lintott DJ, et al. Familial visceral myopathy; a family with involvement of four generations. *Dig Dis Sci* 1992; 37: 464.
6. Arslan M, Bayraktar Y, Oksuzoglu G, et al. Four cases with chronic intestinal pseudo-obstruction due to hollow visceral myopathy. *Hepatogastroenterology* 1999; 46(25): 349-352.

CLINICAL IMAGES

Partial flap avulsion following refractive surgery

Roland R Berger, M D Williams, Clive A Novis

Refractive surgery, mainly laser *in situ* keratomileusis (LASIK), is widely used to correct refractive errors, mainly myopia. It consists of producing a corneal flap, ablating the underlying corneal stroma using laser energy, and repositioning the flap without suturing it to the underlying stroma.

A 58-year-old man presented with blurred vision, pain and photophobia after suffering a minor injury on his right eye from a tree branch. He had had LASIK procedures 13 years ago for both eyes. The eye was congested, there was corneal fluorescein staining, and the corneal flap was partially detached and scrolled up (Fig. 1).

Under local sub-conjunctival anaesthesia the flap was irrigated, cleaned, repositioned and sutured. Methylprednisolone and gentamicin were injected subconjunctivally, and the eye was closed for 24 hours. The following day the eye was quiet with a visual acuity of 6/9 and the subsequent course was uneventful.

After a LASIK procedure the flap adheres to the corneal stroma because of the action of the endothelial pump and because the epithelium grows over the flap's margin. Scarring

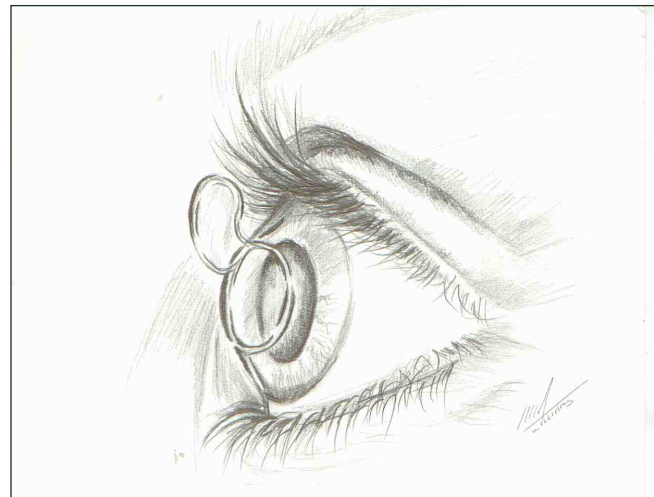


Fig. 1. Schematic representation of the avulsed epithelial flap.

and fibrosis occur only at the flap's margin.¹ Early and late complications are mainly haloes, glare, star-burst and dry eye. A dreaded complication is corneal ectasia.²

Traumatic dislocation has been reported after 10 days,³ 1 year⁴ and 3 years and 5 months.⁵ Our report is the first to indicate the possibility of weak adhesion of the flap after a much longer time, i.e. 13 years.

References

1. Ivarsen A, Laurgen T, Moller-Petersen T. Characterisation of corneal fibrotic wound repair at the LASIK flap margin. *Br J Ophthalmol* 2003; 87(10): 1272-1278.
2. Piccoli P, Gomes AAC, Piccoli FVA. Corneal ectasia detected 32 months after LASIK for correction of myopia and asymmetric astigmatism. *J Catar Ref Surg* 2003; 29(3): 1222-1225.
3. Melki SA, Talamo JH, Demetriades AM. Late traumatic dislocation of laser *in situ* keratomileusis corneal flaps. *Ophthalmology* 2000; 107(12): 2136-2139.
4. Tai M-C, Chen C-H, Chang C-J. Late traumatic dislocation of Lasik corneal flaps. *J Med Sci* 2003; 23(3): 165-166.
5. Tetz M, Werner L, Muller M, Dietze U. Late traumatic lasik flap loss during contact sport. *J Catar Ref Surg* 2007; 33(7): 1332-1335.

Roland R Berger, MD (Padova), Specialist in Ophthalmology (Tel-Aviv), is Senior Consultant at Tambo Memorial Hospital in Boksburg. His main interest is ophthalmic trauma.

Melissa D Williams, MB BCH, is doing her community service at the same hospital.

Clive A Novis, MB BCH, FCS (Ophthalmology), is in private practice. His main interests are cataract and refractive surgery.

Corresponding author: R R Berger (rrberger@yebo.co.za)