



## CLINICAL IMAGES

### Intramyocardial tuberculosis – a rare underdiagnosed entity

Xolani Njovane

In contrast to tuberculous pericarditis, the myocardium is resistant to inflammation but can rarely present with tuberculomas. Ziehl-Neelsen staining often fails to demonstrate acid-fast bacilli, and diagnosis rests on the detection of typical histological changes.

#### Case 1

A 38-year-old man, a fit kick-boxer, known anabolic steroid user and marijuana smoker, collapsed with shortness of breath in the casualty department and died. On autopsy, he was found to be muscular and heavily built, and had cardiomegaly, enlarged paratracheal lymph nodes and pulmonary oedema. His heart had a large fibrous nodular mass in the mitral valve cusp; there were numerous small, infiltrative, white, cheese-like lesions proximal to the aortic valve cusp and extending to the myocardium, and extensive fibrous thickening of the tricuspid valve cusp (Figs 1 and 2).

Histological analysis revealed necrotising caseating granulomatous inflammation, and the Ziehl-Neelsen stain was positive for acid-fast bacilli. The subject's HIV status was not ascertained.

#### Case 2

A 21-year-old man had been nauseous and vomiting for one day, and had bought Gaviscon; he collapsed and died while vomiting into a toilet. He was thin but not emaciated. At autopsy, cardiomegaly was evident, with a firm, hollow, yellowish mass with a thrombus within the cavity, just below the aortic outflow tract in the left ventricle. The aortic valve cusps had been replaced by the mass. The lungs were normal and the lymph nodes enlarged. The subject's HIV status was not ascertained. No acid-fast bacilli were noted on Ziehl-Neelsen staining.

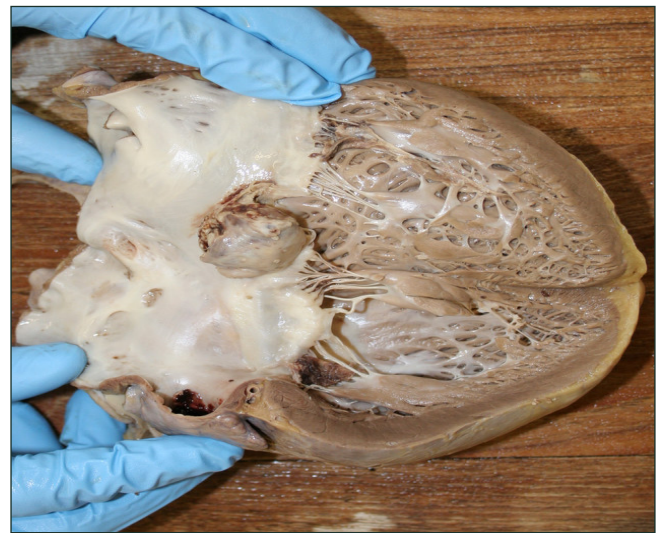

Fig. 1. Large fibrous nodular mass in the mitral valve cusp.

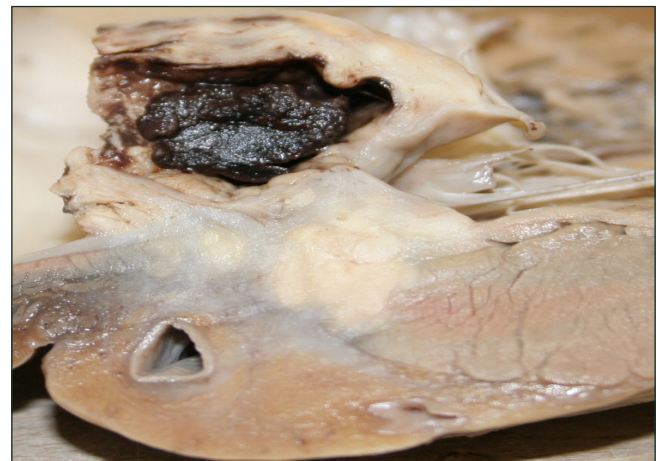


Fig. 2. Numerous small, infiltrative, white, cheese-like lesions proximal to the aortic valve cusp and extending to the myocardium.

#### Discussion

Tuberculosis is rampant in South Africa and, with the exacerbating effects of AIDS, the incidence is likely to rise. Tuberculosis is generally thought to spare the heart, thyroid, pancreas and skeletal muscle; cardiovascular manifestations are largely restricted to chronic pericardial inflammation.

Cardiac tuberculoma was first reported by Maurocordat in 1664 and Morgagni in 1761; Virchow denied the existence of myocardial tuberculosis in 1865 but, in 1902, 72 cases were



reported.<sup>1</sup> In a series of 19 patients at Groote Schuur Hospital over a 27-year period,<sup>2</sup> 1 patient was diagnosed *ante mortem*, 11 were found on autopsy to have nodular lesions, and 7 had miliary lesions; acid-fast bacilli were demonstrated in only 1!

Myocardial tuberculosis spreads from mediastinal lymph nodes, tuberculous pericarditis or retrograde lymphatic and haematogenous spread. The favoured sites are the right atrium and left ventricle. Pathological varieties are nodular/miliary tubercles or diffuse infiltrative tuberculosis of the myocardium.

*Ante mortem* diagnosis is rare; patients may present with arrhythmias, superior vena cava obstruction, right ventricle outflow tract obstruction or left ventricular obstruction. The mechanisms of death include arrhythmias, impaired

myocardial contractility, cardiac rupture, coronary occlusion, and obstruction to pulmonary blood flow leading to fatal haemorrhage.

I thank Dr Isabella Brouwer (forensic pathologist, UCT), Drs Helen Wainright and Maureen Duffield, and Professor Govender (histopathologists, UCT), Professor A Rose (cardiac histopathologist, University of Minnesota Medical School, Minneapolis, USA), Professor B Mayosi (cardiologist, UCT), and Dr Sasha Maistry (registrar, UCT).

1. Biedrzycki OJ, Baithun SI. TB-related sudden death due to myocarditis complicating miliary TB: a case report and literature review. *Am J Forensic Med Pathol* 2006; 27: 335-336.
2. Rose AG. Cardiac tuberculosis: a study of 19 patients. *Arch Pathol Lab Med* 1987; 111: 422-426.

## LETTER FROM MOSCOW

### Roads, partings and Port wine – destinies of Russian intelligentsia

Sergej Jargin

I was genetically predisposed to be thin, round-shouldered and short-sighted but, thanks to canoeing with my uncle, two years of military service, and – from 1977 to 1988 – construction and forestry work during holidays, I was in such good form that some girls took me for an athlete. My last construction job was helping to finish a stadium in a city near the Arctic circle, north of St Petersburg. Temporary workers were taken on because of the short construction period, for which the regular staff did not suffice. We worked on average 16 hours a day without holidays. We levelled the surfaces, laid concrete here and there, and put kerbstones into position. The concrete was carried in a barrow by two men, and the 90 kg kerbstones on crowbars. A kerbstone can be carried on one's own, embraced as a beloved woman, but not so captivating. When the work was nearly finished, a new watchman appeared on the scene.

*'Dr Sergej' practised in South Africa during the 1990s. In contemplative (and occasionally contentious) mood, he reflects on this period, along with some frank autobiographical detail.*

Corresponding author: S Jargin (sjargin@yahoo.com)

Ludmila was a young lady with a technical education and a small son. She came to work at an industrial complex, but someone did not keep his promise, and she had to take the temporary job of night watchman at the stadium. The boy stayed at home in Saransk (capital city of the Mordovian autonomic territory to the south-east of Moscow; the Mordovians are a Finno-Ugric people in central Russia). She chose me probably on the principle of the attraction of extremes: she was a tall and strong girl. 'Come for a cup of tea after work,' she suggested to me while I was digging in a trench.

In manual labour, as in many other things, I overestimated myself; my vertebral column sent feedback through the afferent channels: I should not carry heavy weights. But the work had to be finished, I carried and carried – and Luda was waiting for me in the evenings. 'You are so slim! And not heavy at all, that's why I love you so much.' The barrow became heavier and heavier, and the pain in my spine was getting worse.

The work was finished at last, and we had to separate; we almost cried over two glasses of port. Then we met in Moscow, then I went to see her in Saransk. She asked, 'Do you want me to stay with you?'

'Of course I do! But my aunt from Paris has sent me an invitation, I must go before they close the border again, I will