



CLINICAL IMAGES

Extrinsic bronchial compression by primary tuberculous adenopathy, simulating foreign-body aspiration

Richard Pitcher, John Hewitson

A 5-month-old boy was well until the day before admission, when he developed a cough. On the morning of admission he was irritable and his mother noticed a blue tinge to his lips during episodes of crying. This prompted her to bring him to the emergency unit at Red Cross Children's Hospital, where he was found to be distressed and cyanosed, with a respiratory rate of 60 beats per minute, a heart rate of 200/minute and alar flaring. His left chest showed decreased air entry, bronchial breathing and dullness to percussion. Oxygen saturation was 66%, improving to 88% on face-mask oxygen. His weight was on the 50th percentile. He was well hydrated, well perfused and had no significant background medical history.

A mobile chest radiograph (Fig. 1) showed complete opacification of the left hemithorax, mediastinal deviation to the left and overexpansion of the right lung, which had herniated across the midline. A penetrated anteroposterior (AP) chest radiograph (Fig. 2) showed abrupt 'cut-off' of the left main bronchus.

With a presumptive diagnosis of foreign-body obstruction, urgent bronchoscopy was performed. The trachea was mildly inflamed, showing minimal clear secretions and there was

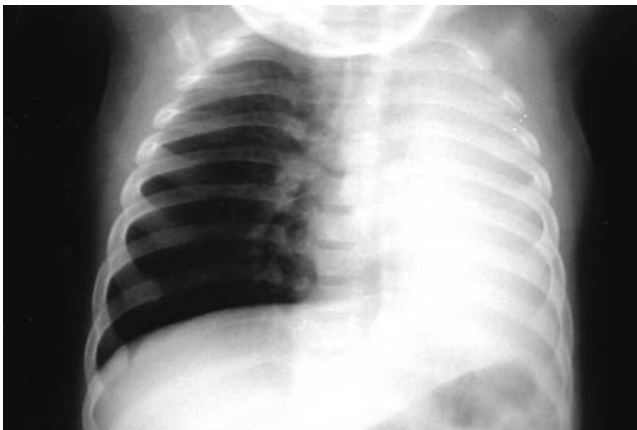

Fig. 1. Admission mobile supine chest radiograph showing complete opacification of the left hemithorax, mediastinal deviation to the left and an over-expanded right lung herniating across the midline.

Richard Pitcher is Head of the Division of Paediatric Radiology and John Hewitson Head of Paediatric Cardiothoracic Surgery, Red Cross War Memorial Children's Hospital, Cape Town.

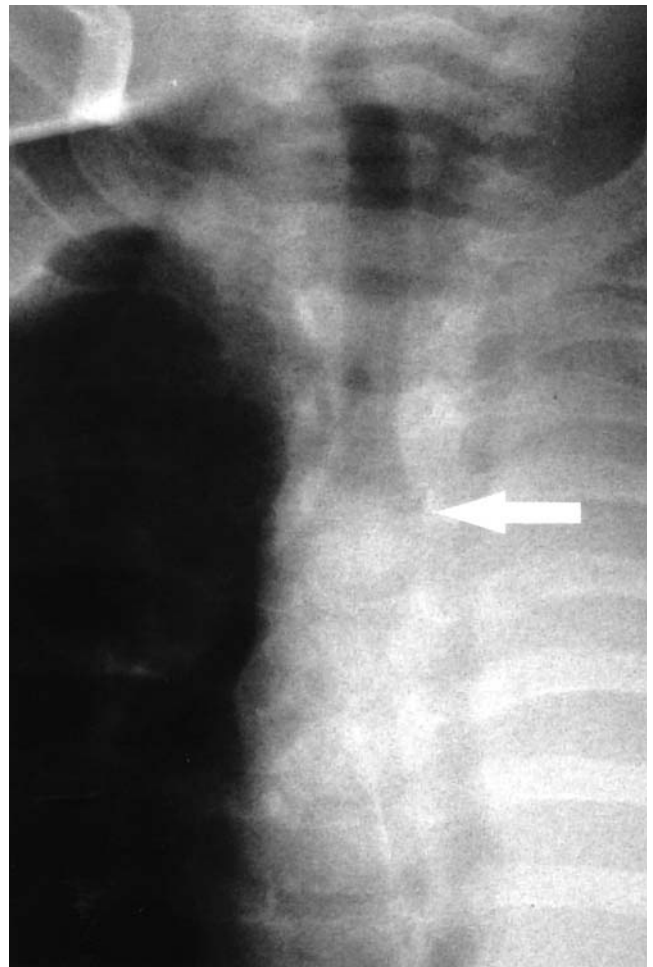


Fig. 2. Penetrated AP chest radiograph showing abrupt 'cut-off' of the left main bronchus, approximately 1 cm from its origin (arrow).

subtle splaying of the carina. The right main bronchus was patent, but its origin was narrowed approximately 30% by extrinsic compression. The left main bronchus was also extrinsically compressed and tapered to complete occlusion 10 mm from its origin. A 3 mm rigid bronchoscope was easily passed through the obstruction, to reveal inflamed but intact mucosa throughout, with minimal creamy secretions in the distal airways. A presumptive diagnosis was made of bronchial compression by tuberculous lymph nodes. Steroids and antituberculous therapy were started, pending confirmation of the diagnosis.



The following day oxygen saturation in room air was 100% and a repeat chest radiograph (Fig. 3) showed complete re-expansion of the left lung. A computed tomography (CT) scan performed the same day confirmed the presence of subcarinal adenopathy (Fig. 4).

Bronchial lavage proved negative for acid-fast bacilli and other micro-organisms, but the Mantoux skin test was reactive.

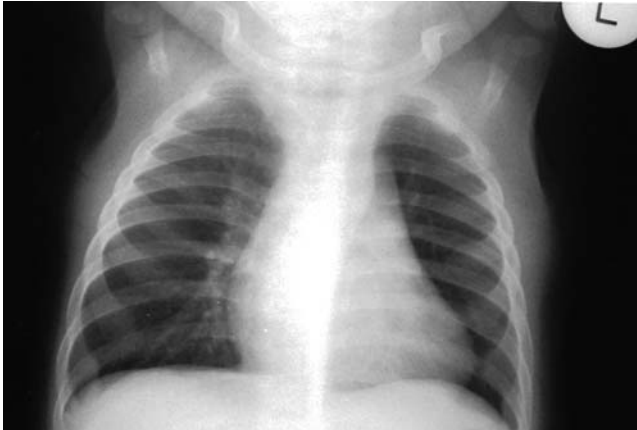

Fig. 3. Normal follow-up AP chest radiograph one day after admission.

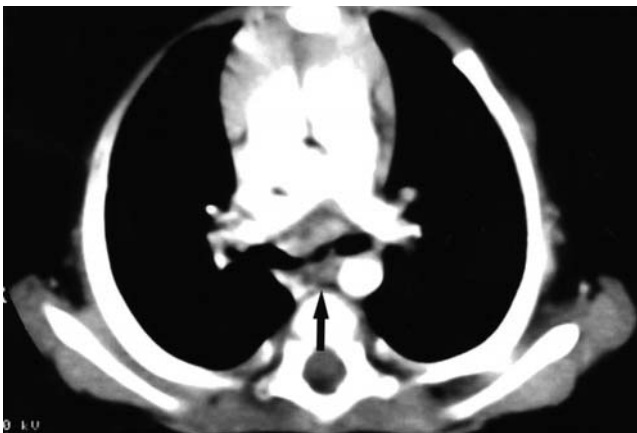

Fig. 4. Contrast-enhanced axial CT scan of the chest just below the level of the carina, showing subcarinal adenopathy (arrow).

Discussion

Paediatric chest radiographs showing unequal lung size and aeration, with mediastinal deviation towards the opacified side are a diagnostic challenge in the face of acute respiratory symptoms. Which side is abnormal? Is the over-expanded lung pathological, displacing the mediastinum and compressing its normal counterpart, or is it simply expanding in the face of contralateral lung collapse? As a general rule, the side that shows the least respiratory excursion is the pathological side. This can be assessed clinically or under fluoroscopy. In practice, however, the distinction is academic.

Regardless of whether the expanded or collapsed lung is pathological, the child needs bronchoscopy, because bronchial obstruction can cause either picture, depending on the degree of occlusion. With complete obstruction comes complete collapse. If obstruction is incomplete, the airway is patent when it widens during inspiration, but obstructs as it narrows in expiration. This ball-valve effect can result in a grossly over-expanded lung with significant compression of the opposite lung, but never to the extent that air is completely obliterated at the contralateral costophrenic angle.¹

Broadly, obstruction to a hollow viscus can have its cause in the lumen, in the wall or outside the wall.

Almost all cases of endobronchial obstruction in childhood are due to foreign-body aspiration or mucous plugging. When radiological features suggest bronchial obstruction, foreign-body aspiration has to be the prime consideration. Linegar *et al.*² documented local experience of this entity, showing that 80% of cases involve children under 5 years of age, that in most instances the classic clinical triad of choking followed by ipsilateral wheezing and decreased air entry are not present, and in more than half, the diagnosis is delayed beyond 24 hours. Therefore, the index of clinical suspicion has to be high to address the condition's ongoing high morbidity, which increases with diagnostic delay. Peanuts are most commonly implicated. Foreign-body aspiration remains a cause of mortality in our local population and worldwide.

The compliant paediatric tracheobronchial tree is particularly vulnerable to extrinsic compression. Although aberrant vessels, enlarged cardiac chambers, congenital foregut cysts and neoplastic nodes have this potential, tuberculous adenopathy is the commonest cause in our patient population. Mediastinal adenopathy can be considered the hallmark of primary pulmonary tuberculosis in childhood, demonstrated on plain radiographs in more than 90% of cases. There need not be associated demonstrable parenchymal pathology.³ CT evaluation⁴ has shown multiple sites of involvement in more than 80% of cases, with subcarinal, hilar and anterior mediastinal nodes being most commonly involved and causing some degree of bronchial narrowing in one-quarter of cases. Acute respiratory distress precipitated by bilateral critical narrowing of the main bronchi between enlarged tuberculous nodes is well recognised, and local experience of its surgical management has been recorded.⁵ There has been a single documented case of tuberculous adenopathy causing incomplete or 'ball-valve' obstruction to the right main bronchus with resultant pulmonary hyperinflation.⁶ To the best of our knowledge this is the first recorded case of acute, complete, unilateral obstruction to a main bronchus by tuberculous adenopathy, with complete lung collapse simulating foreign-body aspiration.

Intramural causes of bronchial obstruction are extremely rare in the paediatric age group. However there have been isolated reports of endobronchial tuberculosis simulating



foreign-body aspiration.^{7,9} This is thought to result from lymphatic spread to the mucosal surface of the bronchial tree, with granuloma formation.

Conclusion

We have documented what is believed to be a previously undescribed presentation of primary pulmonary tuberculosis in childhood, entrenching the reputation of the tubercle bacillus as the great clinical pretender.

1. Swischuk LE. *Differential Diagnosis in Paediatric Radiology*. Baltimore: Williams and Wilkins, 1984; 7-12.
2. Linegar AG, von Oppel UO, Hegemann S, de Groot M, Odell JA. Tracheobronchial foreign bodies. *S Afr Med J* 1992; 82: 164-167.
3. Leung AN, Müller NL, Pineda PK, FitzGerald JM. Primary tuberculosis in childhood: radiographic manifestations. *Radiology* 1992; 182(1): 87-91.
4. Andronikou S, Joseph E, Lucas S, et al. CT scanning for the detection of tuberculous mediastinal and hilar lymphadenopathy in children. *Pediatr Radiol* 2004; 34: 232-236.
5. Worthington MC, Brink JC, Odell JA, et al. Surgical relief of acute airway obstruction due to primary tuberculosis. *Ann Thorac Surg* 1993; 56: 1054-1062.
6. Pereira KD, Mitchell KB, Eyen TP, Lazar RH. Tuberculous lymphadenopathy masquerading as a bronchial foreign body. *Pediatr Emerg Care* 1997; 13: 329-330.
7. Caglayan S, Cotei I, Acar U, Erkin S. Endobronchial tuberculosis simulating foreign body aspiration. *Chest* 1989; 95: 1164.
8. Gupta A, Narasimhan KL. Endobronchial tuberculosis and the surgeon. *Indian Pediatr* 2002; 39: 977.
9. Park AH, Fowler SS, Challapalli M. Suspected foreign body aspiration in a child with endobronchial tuberculosis. *Int J Pediatr Otorhinolaryngol* 2000; 53(1): 67-71.