

CASE REPORT

# Boomslang (*Dispholidus typus*) envenomation in a patient on warfarin therapy

C Corbett, BSc (Chemical Biology), 5th-year medical student; V Pillay-Fuentes Lorente, MB ChB, PG Dip (Med Dev); G J Muller, BSc, MB ChB, BSc (Pharm) Hons, MMed (Anaes), PhD (Toxicology); R van Rensburg, MB ChB, Dip HIV Man (SA)

Division of Clinical Pharmacology, Department of Medicine, Faculty of Medicine and Health Sciences, Stellenbosch University, Cape Town, South Africa

Corresponding author: R van Rensburg (22428585@sun.ac.za)

The venom of the boomslang (*Dispholidus typus*) has potent effects on the coagulation system. It is known to produce a venom-induced consumptive coagulopathy (VICC) through the proposed activation of clotting factor II (prothrombin), factor X, and possibly factor IX. Warfarin, an anticoagulant medication, decreases the circulating vitamin K-dependent clotting factors II, VII, IX and X. We report a unique case of a boomslang bite in a patient on warfarin therapy. During the patient's hospital stay he developed abnormal clotting profiles indicating an underlying VICC, but without major bleeding. He received monovalent antivenom and recovered with no complications. We discuss two possible outcomes of a boomslang bite in a patient on warfarin therapy, exploring the underlying pathophysiology that could lead to the presentation of a reduced risk of overall bleeding or, alternatively, that the bleeding could be compounded and exacerbated. It is possible that in our case the anticoagulant effect of warfarin was wholly obscured by the VICC of the boomslang venom. The composition of the snake venom may have been a contributory factor in the reduced clinical bleeding observed.

S Afr Med J 2020;110(10):999-1002. <https://doi.org/10.7196/SAMJ.2020.v110i10.15137>

The boomslang (*Dispholidus typus*) is a rear-fanged arboreal snake of the colubrid family that may cause fatal envenomation. An unremarkable bite may cause a serious venom-induced consumptive coagulopathy (VICC) through the proposed activation of clotting factor II (prothrombin), factor X, and possibly factor IX (Fig. 1).<sup>[1,2]</sup> In addition to prothrombin activation, several other mechanisms have been proposed that contribute to the clinical envenomation syndrome.<sup>[3]</sup> In contrast, the anticoagulant medication warfarin reduces the functional pool of vitamin K-dependent clotting factors II, VII, IX and X by inhibiting the vitamin K epoxide reductase C1 (VKORC1) enzyme to produce the anticoagulant effect.<sup>[4]</sup> Few cases of boomslang bite have been described in the literature, and the interaction of boomslang venom with warfarin on the coagulation system is unknown.<sup>[5-14]</sup> To our knowledge, this is the first description of boomslang envenomation in a patient on warfarin therapy.

## Case report

A 45-year-old white man from Northern Cape Province, South Africa, was bitten by a snake on the left hand while trimming a hedge (Fig. 2). He applied a tourniquet to the left forearm, and took photos of the snake. He presented to medical services

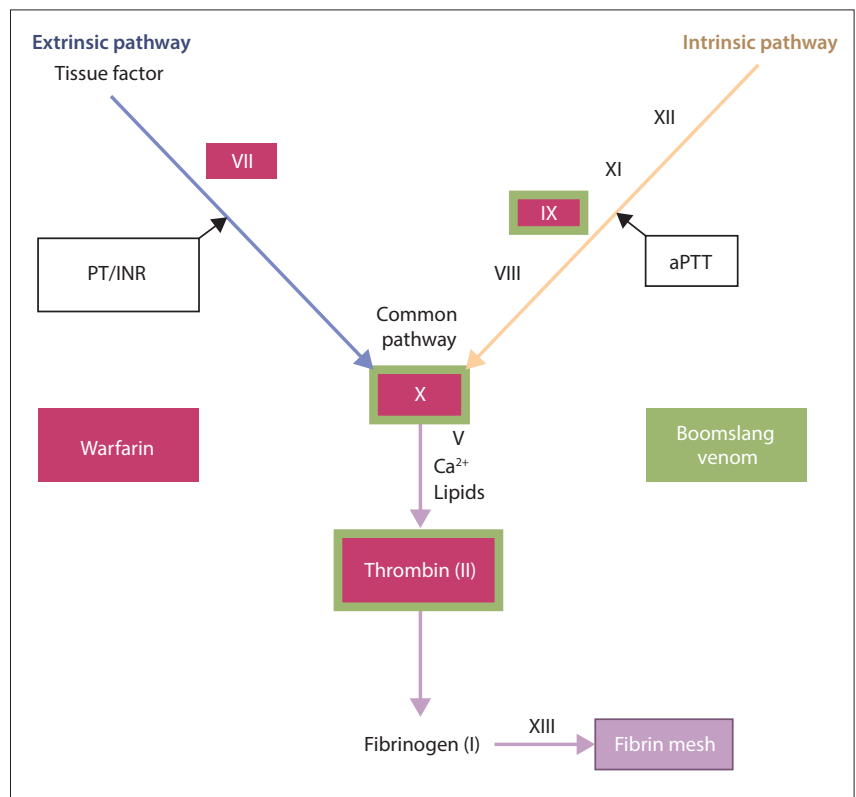


Fig. 1. Overview of warfarin and boomslang venom effect on the coagulation cascade. Warfarin (red boxes) reduces functional levels of vitamin K-dependent clotting factors II, VII, IX and X. It is thought that boomslang venom (green boxes) activates factors II (prothrombin to thrombin), X and IX, leading to fibrinogen depletion and consumptive coagulopathy. (PT = prothrombin time; INR = international normalised ratio; aPTT = activated partial thromboplastin time.)

2 hours after the bite, and was transferred to a referral hospital (Fig. 3). The snake was subsequently identified from the photos by a snake expert as a boomslang. The patient had a notable medical history of previous pulmonary embolism requiring warfarin therapy. The international normalised ratio (INR) measurements during the preceding 9 months had been within the therapeutic range.

On examination there was oozing from the bite marks and at the venepuncture site. No petechiae or ecchymoses were noted, but the patient developed a small haematoma over the deltoid area where antitetanus toxoid was injected. There were no features of shock, disseminated intravascular coagulation or renal failure. The blood biochemistry was essentially normal.

The patient remained asymptomatic 5 hours after the bite, despite the clotting profile becoming severely deranged (Table 1). The attending clinician decided to administer two 10 mL ampoules of monovalent boomslang antivenom intravenously 6 hours after the bite. Promethazine 25 mg and hydrocortisone 100 mg were also administered for prevention of allergic reactions from intravenous antivenom immunoglobulins. Shortly after the antivenom infusion was initiated, however, the patient developed severe rigors and became hypotensive, with a systolic blood pressure of 69 - 80 mmHg that was treated with intravenous fluid administration. The hypotension slowly resolved within 12 hours, and the patient was lucid throughout. He did not receive any interventions to treat warfarin toxicity such as vitamin K therapy or replacement

blood products such as plasma. Follow-up clotting profiles showed significant improvement (Table 1), and the patient's clotting profile normalised ~18 hours after antivenom administration. No other complications or clinical bleeding were reported. He remained stable after antivenom administration and was subsequently discharged on day 3.

Informed consent was obtained from the patient for the sharing of this information.

### Discussion

The boomslang is a slender snake with a short head and characteristically large eyes. They are widely distributed in sub-Saharan Africa. The average adult length is 120 - 155 cm. Most boomslang have green colouring, although colours may vary to red-black, yellow or brown.<sup>[10]</sup> They are shy and timid snakes, but when cornered inflate the anterior part of the body.<sup>[10,15]</sup> Typical manifestations of envenomation occur 4 - 24 hours after a bite, usually as mucosal or dermal bleeds, or bleeding from sites of iatrogenic skin penetration. Severe VICC may lead to intracranial haemorrhage and multiple organ failure.<sup>[15]</sup>

The major component of boomslang venom causing VICC is reported to be PIII snake-venom metalloproteases (SVMs), acting as a coagulant disruptor.<sup>[3,16]</sup> Boomslang venom exerts further coagulopathic effects via platelet disruption from disintegrins (also SVMs) and phospholipase A<sub>2</sub>. Additional postulated mechanisms include vessel wall disruption through proteolytic enzymes such as three-finger toxin and cysteine-rich secretory protein.<sup>[3]</sup> Tissue factors, vascular pores and vascular permeability may also affect the clinical course of envenomation. It is therefore not possible to predict the exact clinical outcome in advance, as venom composition can vary by region and be affected by the snake's diet and age.<sup>[3]</sup> Boomslang antivenom is a monovalent, equine-derived immunoglobulin that binds to and causes neutralisation of the toxins in the venom.<sup>[15,17]</sup> This process is thought to prevent further binding of the toxin to various tissues and halts the VICC process.<sup>[1]</sup>

Boomslang venom and warfarin may have potentially interacting effects on coagulation and clinical bleeding based on their respective mechanisms of action. Two scenarios may be considered: firstly, overall bleeding is reduced, or secondly, bleeding is compounded and exacerbated. The first scenario stems from the rationale that the mechanism of anticoagulation induced by warfarin is mediated through the reduction of functional levels of vitamin K-dependent clotting factors. This reduction may paradoxically have a protective

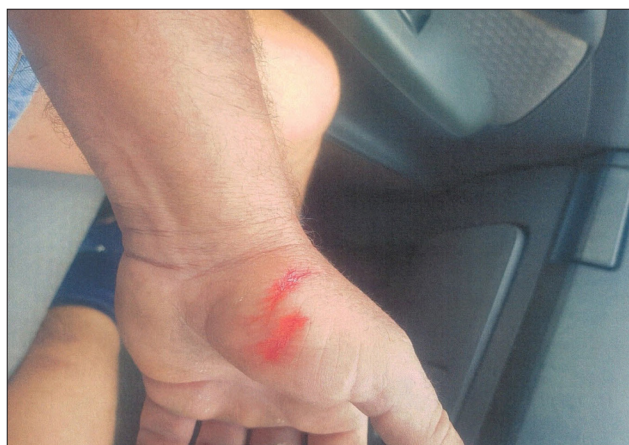

Fig. 2. The unremarkable bite site on the left hand of the patient, with some blood oozing from the puncture wounds.

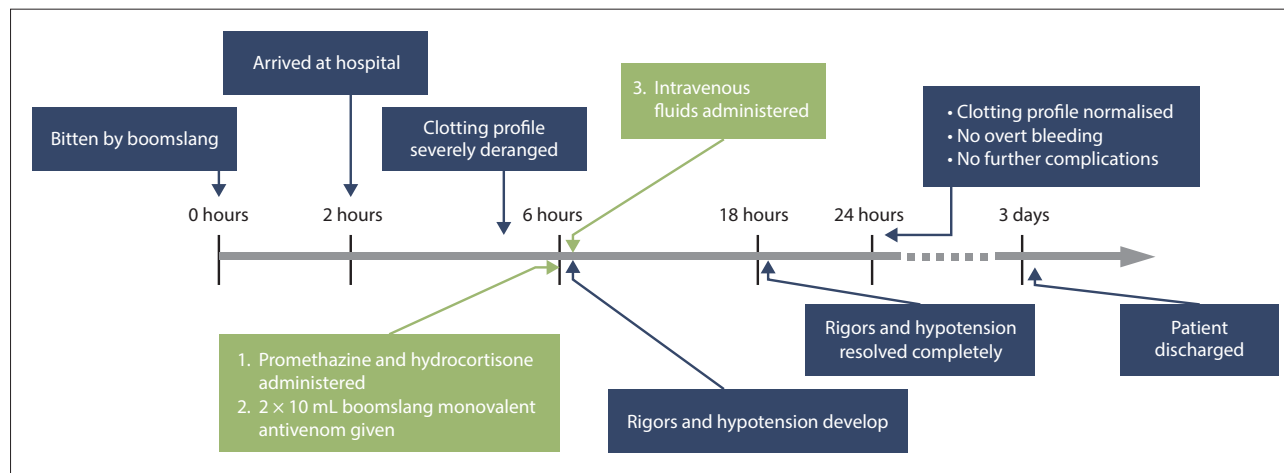


Fig. 3. Timeline of the clinical course of envenomation. Green boxes depict administration of medications.

Table 1. Clotting profile over the course of the envenomation\*

| Test (units)         | Reference range | Time (hours post envenomation) |   |      |      |      |      |
|----------------------|-----------------|--------------------------------|---|------|------|------|------|
|                      |                 | 5                              | 6 | 13   | 24   | 41   | 72   |
| INR                  | 0.9 - 1.3       | >10                            |   | 4.3  | 2.5  | 2.2  | 1.8  |
| Prothrombin time (s) | n/a             | >120                           |   | 48.2 | 29.3 | 26.4 | 21.7 |
| Control time (s)     | n/a             | 12.3                           |   | 12.3 | 12.3 | 12.3 | 12.3 |
| aPTT patient (s)     | 25.4 - 38.4     | >180                           |   | 44.2 | 34.6 | 32.9 | 28.9 |
| aPTT control (s)     | n/a             | 29.5                           |   | 29.5 | 29.0 | 29.2 | 31.0 |
| D-dimer (µg/mL)      | <0.50           | >10                            |   | >10  | >10  | >10  | >10  |
| Fibrinogen (g/L)     | 2.2 - 5.0       | >4.0                           |   | >4.0 | 1.4  | 2.0  | 2.9  |

INR = international normalised ratio; aPTT = activated partial thromboplastin time; n/a = not applicable.  
\*Green highlight indicates values outside reference range.

function, as there may be fewer functional clotting factors available for the boomslang venom to activate, with an attenuated VICC response. Evidence for this proposed mechanism was described using venom from the pit viper *Bothrops jararaca*, with a similar coagulopathic presentation to the boomslang. Researchers depleted VKDCF in rats using warfarin and, after administration of the venom, showed that VICC was biochemically reduced compared with un-warfarinised controls.<sup>[18]</sup> In humans, therapeutic doses of warfarin reduce levels of clotting factors II and X to 20 - 40% and 15 - 25% of baseline levels, respectively.<sup>[19,20]</sup> This reduction correlates clinically with an INR of 2 - 3, which is considered the desired range for most indications for warfarin. Above this INR range the probability of bleeding is more likely, and a critical threshold is reached where the level of clotting factors and the INR no longer correlate.<sup>[20]</sup>

The second scenario assumes that although warfarin reduces the amount of functional clotting factors available, the remaining factors may still be activated by the boomslang venom. This may result in an even greater depletion of the remaining VKDCF, and an augmented VICC. The clinical implication is a significantly increased risk of bleeding. The underlying mechanisms predicting clinical bleeding are, however, undoubtedly more complex. A variation in composition, such as more SVMP coagulant disruptors and fewer blood vessel disruptors, may explain the severely deranged clotting profile and lack of significant clinical bleeding observed in our case.

Either of the above scenarios may hold true in our case: the first scenario has potential in that the patient did not develop evident clinical features prior to administration of the antivenom, although it is well documented that boomslang envenomation may have a significant delay in the presentation of overt clinical features.<sup>[11]</sup> Nevertheless, rapid deterioration in some patients has been reported,<sup>[7]</sup> but was not observed in this case despite the severely deranged clotting profile. The patient's clotting profile supports the second scenario more strongly: the INR and activated partial thromboplastin time were significantly increased, presumably indicating involvement of the extrinsic, intrinsic and common pathways of the coagulation cascade. Fibrinogen degradation products were also significantly raised, indicating that a process of consumptive coagulopathy did indeed occur despite warfarin reducing the number of functional clotting factors. However, considering that the patient did not develop signs and symptoms of overt clinical bleeding, it is reasonable to consider that the effect of warfarin on the coagulation cascade was possibly overcome by the effects of the boomslang venom. Possible reasons for the presentation may have been that the composition of the snake venom affected intravascular coagulation more than blood vessel disruption, or that the time from envenomation to antivenom administration was too short for significant clinical bleeding to occur.

## Conclusions

This unique case description provides insight into the underlying mechanisms of the interaction of warfarin and boomslang venom. It is likely that in this case the anticoagulant effect of warfarin was overridden by the VICC of the boomslang venom, and that the boomslang's venom composition contributed to the fact that the patient did not develop major bleeding before the administration of antivenom. Meticulous recording of similar rare cases may validate the abovementioned theories, and clinicians may thus be equipped to manage such patients well. Further research is needed to elucidate the pathophysiology of the interaction.

## Teaching points

- A boomslang bite may cause an acute venom-induced consumptive coagulopathy through the proposed activation of clotting factors II, X and possibly IX.
- In contrast, warfarin reduces the functional pool of vitamin K-dependent clotting factors II, VII, IX and X by inhibiting the VKORC1 enzyme to produce the anticoagulant effect.
- Boomslang venom and warfarin may have potentially interacting effects on coagulation and clinical bleeding based on their respective mechanisms of action.
- Individual snake venom composition may alter the clinical presentation.
- Boomslang antivenom is an effective antidote.

**Declaration.** None.

**Acknowledgements.** None.

**Author contributions.** All authors contributed equally.

**Funding.** None.

**Conflicts of interest.** None.

1. White J. Snake venoms and coagulopathy. *Toxicon* 2005;45(8):951-967. <https://doi.org/10.1016/j.toxicon.2005.02.030>
2. Debono J, Dobson J, Casewell NR, et al. Coagulating colubrids: Evolutionary, pathophysiological and biodiscovery implications of venom variations between boomslang (*Dispholidus typus*) and twig snake (*Thelornis mossambicanus*). *Toxins (Basel)* 2017;9(5):171. <https://doi.org/10.3390/toxins9050171>
3. Pla D, Sanz L, Whiteley G, et al. What killed Karl Patterson Schmidt? Combined venom gland transcriptomic, venomic and antivenomic analysis of the South African green tree snake (the boomslang), *Dispholidus typus*. *Biochim Biophys Acta Gen Subj* 2017;1861(4):814-823. <https://doi.org/10.1016/j.bbagen.2017.01.020>
4. Patel S, Singh R, Preuss CV, Patel N. Warfarin. *StatPearls* 2020:1-5. <https://www.ncbi.nlm.nih.gov/books/NBK470313/> (accessed 11 May 2020).
5. Reitz CJ. Boomslang bite - time of onset of clinical envenomation. *S Afr Med J* 1989;76(1):39-40.
6. Krüger HJ, Lemke FG. Fatal boomslang bite in the Northern Cape. *Afr J Emerg Med* 2019;9(1):53-55. <https://doi.org/10.1016/j.afjem.2018.12.006>
7. Gomperts ED, Demetriou D. Laboratory studies and clinical features in a case of boomslang envenomation. *S Afr Med J* 1977;51(6):173-175.
8. Geddes J, Thomas JE. Boomslang bite - a case report. *Cent Afr Med J* 1985;31(6):109-112.
9. Aitchison JM. Boomslang bite - diagnosis and management: A report of 2 cases. *S Afr Med J* 1990;78(1):39-42.
10. Du Toit DM. Boomslang (*Dispholidus typus*) bite: A case report and a review of diagnosis and management. *S Afr Med J* 1980;57(13):507-510.
11. Wagener M. Haemotoxic snakebite in rural KwaZulu-Natal, South Africa: A case presenting with haematemesis. *S Afr Med J* 2016;106(5):459-460. <https://doi.org/10.7196/SAMJ.2016.v106i5.9124>

12. Gerber JDW, Adendorff HPF. Boomslang (*Dispholidus typus*) bite: A case report. *S Afr Med J* 1980;57(17):710-711.
13. Matell G, Nyman D, Werner B. Consumption coagulopathy caused by a boomslang bite: A case report. *Thromb Res* 1973;3(2):173-182. [https://doi.org/10.1016/0049-3848\(73\)90067-4](https://doi.org/10.1016/0049-3848(73)90067-4)
14. Nicolson IC, Ashby PA, Johnson ND, Versey J, Slater L. Boomslang bite with haemorrhage and activation of complement by the alternate pathway. *Clin Exp Immunol* 1974;16(2):295-299.
15. Muller GJ, Modler H, Wium CA, et al. Snake bite in southern Africa: Diagnosis and management. *CME* 2012;30(10):362-382.
16. Debono J, Dashevsky D, Nouwens A, Fry BG. The sweet side of venom: Glycosylated prothrombin activating metalloproteases from *Dispholidus typus* (boomslang) and *Thelotornis mossambicus* (twig snake). *Comp Biochem Physiol C Toxicol Pharmacol* 2020;227:108625. <https://doi.org/10.1016/j.cbpc.2019.108625>
17. Marais J. Snakebite. In: Marais J, ed. *Snakes of Southern Africa*. Cape Town: Struik, 2011:40-41.
18. Senise LV, Yamashita KM, Santoro ML. *Bothrops jararaca* envenomation: Pathogenesis of hemostatic disturbances and intravascular hemolysis. *Exp Biol Med* 2015;240(11):1528-1536. <https://doi.org/10.1177/1535370215590818>
19. Solvik UO, Roraas T, Petersen PH, Stavelin A, Monsen G, Sandberg S. The influence of coagulation factors on the in-treatment biological variation of international normalized ratio for patients on warfarin. *Scand J Clin Lab Invest* 2014;74(6):470-476. <https://doi.org/10.3109/00365513.2014.902098>
20. Costa IM, Serralheiro AI, Rodrigues M, Alves G, Falcão AC. Usefulness of factor II and factor X as therapeutic markers in patients under chronic warfarin therapy. *Biomed Pharmacother* 2010;64(2):130-132. <https://doi.org/10.1016/j.biopha.2009.09.020>

Accepted 4 August 2020.