

Foreign body ingestion in children presenting to a tertiary paediatric centre in South Africa: A retrospective analysis focusing on battery ingestion

J A Chabilall,¹ MB BCh, DCH, DA, FCA, MMed; J Thomas,² BSc, HED, MB ChB, FFA;
R Hofmeyr,³ MB ChB, DipPEC, DA, MMed, FCA, FAWM

¹ Department of Anaesthesia and Critical Care, Tygerberg Hospital, Cape Town, South Africa

² Department of Anaesthesia and Perioperative Medicine, Faculty of Health Sciences, University of Cape Town, and Red Cross War Memorial Children's Hospital, Cape Town, South Africa

³ Department of Anaesthesia and Perioperative Medicine, Faculty of Health Sciences, University of Cape Town, and Groote Schuur Hospital, Cape Town, South Africa

Corresponding author: R Hofmeyr (ross.hofmeyr@uct.ac.za)

Background. Ingestion of foreign bodies remains a frequent reason for presentation to paediatric emergency departments worldwide. Among the variety of objects ingested, button batteries are particularly harmful owing to their electrochemical properties, which can cause extensive injuries if not diagnosed and treated rapidly. International trends show an increasing incidence of button battery ingestion, leading to concern that this pattern may be occurring in South Africa. Limited local data on paediatric foreign body ingestion have been published.

Objectives. To assess battery ingestion rates in a tertiary paediatric hospital. We hypothesised that the incidence has increased, in keeping with international trends. Secondary objectives included describing admission rates, requirements for anaesthesia and surgery, and promoting awareness of the problems associated with battery ingestion.

Methods. We performed a retrospective, descriptive analysis of the Red Cross War Memorial Children's Hospital trauma database, including all children under 13 years of age seen between 1 January 2010 and 31 December 2015 with suspected ingestion of a foreign body. The ward admissions database was then examined to find additional cases in which children were admitted directly. After exclusion of duplicate records, cases were classified by type of foreign body, management, requirement for admission, anaesthesia and surgery. Descriptive statistics were used to analyse the data in comparison with previous studies published from this database.

Results. Patient age and gender patterns matched the literature, with a peak incidence in children under 2 years of age. Over the 6-year period, 180 patients presented with food foreign bodies, whereas 497 objects were classified as non-food. After exclusion of misdiagnosed cases, the remaining 462 objects were dominated by coins (44.2%). Batteries were the causative agent in 4.8% (22/462). Although the subtypes of batteries were not reliably recorded, button batteries accounted for at least 64% (14/22). Most children who ingested batteries presented early, but more required admission, anaesthesia and surgery than children who ingested other forms of foreign body.

Conclusions. The study demonstrated that the local incidence of button battery ingestion may be increasing, although data are still limited. Admission, anaesthesia and surgery rates for batteries were higher in this cohort than for all other foreign bodies. As button batteries can mimic coins, with much more dire consequences on ingestion, our ability to expedite diagnosis and management hinges on a high index of suspicion. It is imperative to increase awareness among healthcare workers and parents.

S Afr Med J 2020;110(7):652-656. <https://doi.org/10.7196/SAMJ.14481.v110i7.14481>

Ingestion of foreign bodies and substances remains an important reason for presentation to paediatric emergency departments worldwide.^[1-4] Among the great variety of objects which are ingested, button batteries are particularly harmful owing to their electrochemical properties, which can cause extensive injuries if not diagnosed and treated rapidly.^[5-10] International trends have shown an increased incidence of ingestion of button batteries in recent years,^[9-14] leading to concern that this pattern may be occurring in South Africa (SA). Societal factors which could be driving this change include increased population (especially in the 0 - 9-year age group), population shift into urban areas, and increased employment opportunities in some provinces which, coupled with higher incomes, may translate to a larger number of children in a susceptible age group gaining access to battery-operated toys.^[15]

Limited local data on paediatric foreign body ingestion have been published. Since 1991, records have been maintained for all patients

presenting to a single, dedicated paediatric trauma unit at Red Cross War Memorial Children's Hospital (RCWMCH) by the Child Accident Prevention Foundation of Southern Africa (CAPFSA) database. Van As *et al.*^[11] published an initial series of suspected ingestion cases from 2001 - 2002 from this database in 2003. Although this work did not specifically report incidence of battery ingestion, it was followed by an 18-year cohort (1991 - 2009) by Timmers *et al.*^[16] in 2012 and data from 2010 by Delpont *et al.*^[3] in 2015 which included battery ingestion rates of 2% and 5%, respectively. A similar study including 3 years of data from Pietermaritzburg published in 2018 reported a rate of 5.6%.^[4]

The intention of the present study was to assess battery ingestion rates in the same tertiary-level Cape Town paediatric hospital over the period between 1 January 2010 and 31 December 2015. We hypothesised that the incidence of battery ingestion had increased in line with international trends. Secondary aims included describing

admission and surgery rates, requirements for anaesthesia and intensive care admission, and promoting awareness of the problems associated with battery ingestion.

Methods

Since establishment of the CAPFSA trauma database at RCWMCH in 1991, an admission form has been completed for every child on presentation, which is captured into a Microsoft Access database. After ethics committee and institutional approval (ref. no. UCT HREC 755/2017), the data required for this study were extracted from the CAPFSA database using the search words 'foreign body' and 'ingestion.'

All children under the age of 13 who were admitted to the trauma unit at RCWMCH with a suspected foreign body ingestion were included. A further search was then conducted in the electronic ward admissions database to identify patients who might have been directly referred and ensure that all foreign body admissions had been captured. The additional 194 cases identified were scrutinised and cross-checked using patient identifying data to detect 14 duplicate records, which were removed from the data set. Where available, clinical notes were consulted to confirm the subtype of foreign body and more detailed management. The data were examined using descriptive statistics.

Results

Based on history at presentation, 180 patients over the 6-year period (~30 per annum) were documented as having food (rather than non-edible) foreign bodies. However, final records showed that several were initially misdiagnosed, and they were included in the correct categories in our analysis. A total of 497 ingestions were classified as non-food at presentation, of which 6 (1.2%) were later identified to be foodstuffs (excluding bones). In 29 cases (5.8%), no foreign body was found or identified on further investigation. The classification of the remaining 462 foreign bodies (~75 per annum) is illustrated in Fig. 1. The most frequently ingested foreign body was coins (44.2%). Batteries were the offending agent in 4.8% (22/62). Although the subtypes of batteries were not reliably recorded, button batteries accounted for at least 64% of battery ingestions (14/22).

Overall, foreign body ingestion peaked between 1 and 2 years of age and diminished steadily thereafter (Fig. 2). Fifty-five percent of ingestions occurred in boys. This pattern was similar for battery ingestion, with all but

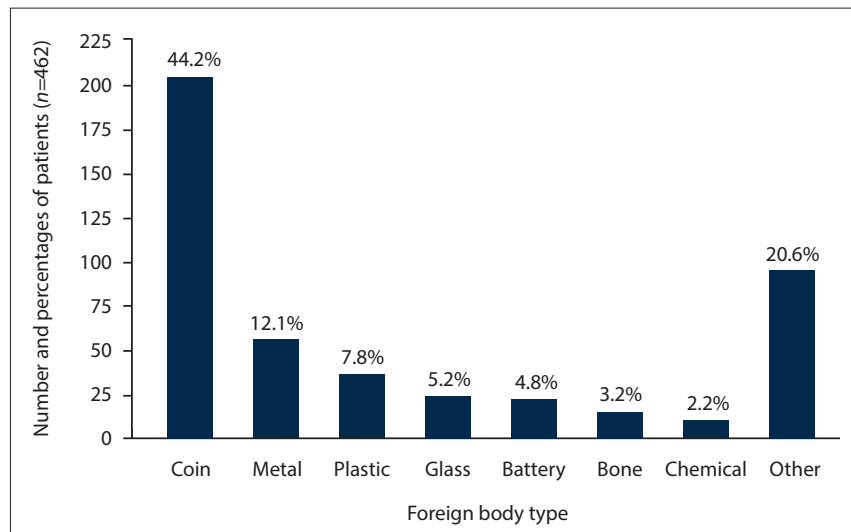


Fig. 1. Type of foreign body ingested.

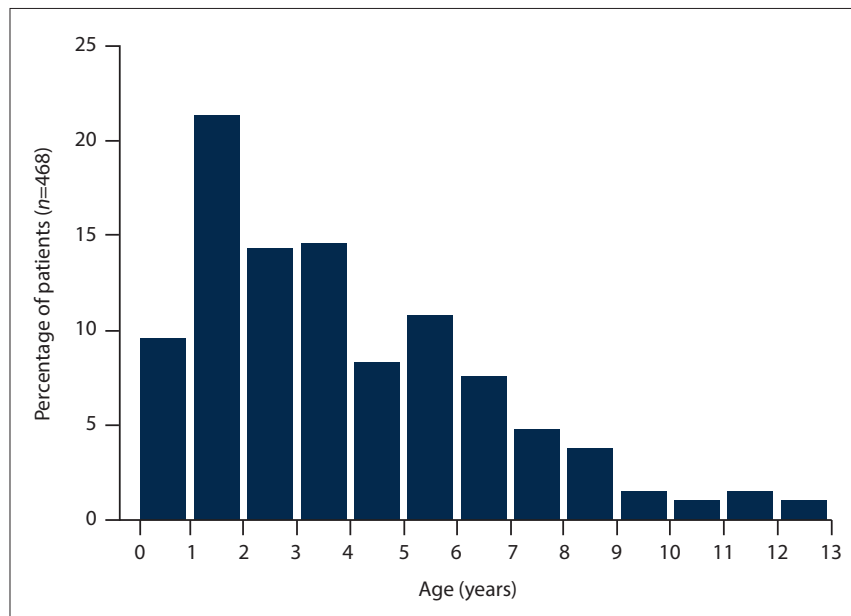


Fig. 2. Age of patient at time of presentation (all foreign bodies) (n=468).

one case occurring in children younger than 5 years, and equal distribution between the genders (Fig. 3).

Data documenting time from ingestion to presentation were not always collated. Most children who had ingested batteries presented early to a healthcare facility, with 59% arriving within 2 hours and only 2 (4.4%) presenting more than 6 hours after ingestion (Fig. 4). Neither the trauma unit database nor the patient notes allowed determination of the symptoms at presentation, or where the foreign body had become lodged.

Most children with confirmed battery ingestion required admission, with 45.5% admitted to intensive care or surgical wards, and 18.2% held in the trauma unit

for observation. More than a third (36.4%) required a general anaesthetic for surgical removal. By comparison, for all foreign bodies, only 46.4% of children were admitted or observed, and 15.6% required anaesthesia (Fig. 5).

Discussion

Batteries accounted for 4.8% of non-food foreign bodies ingested by children presenting to RCWMCH in the 6-year period from 2010 to 2015. Although the type was not always recorded, button batteries accounted for at least 64%. Patients with battery ingestion required admission, general anaesthesia and surgical removal more frequently than any other type of foreign body, including chemicals. All 14 patients with confirmed

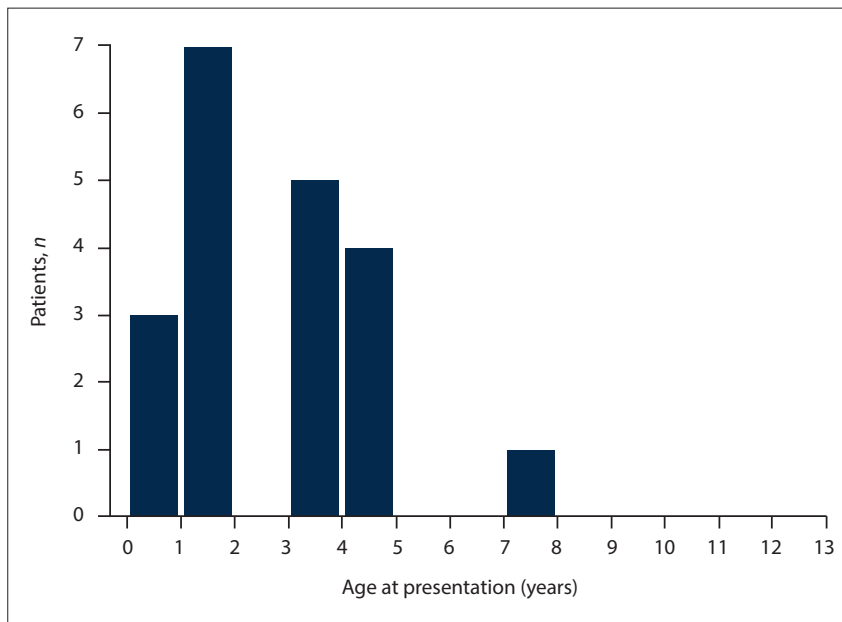


Fig. 3. Age of patient at time of suspected button battery ingestion (n=22).

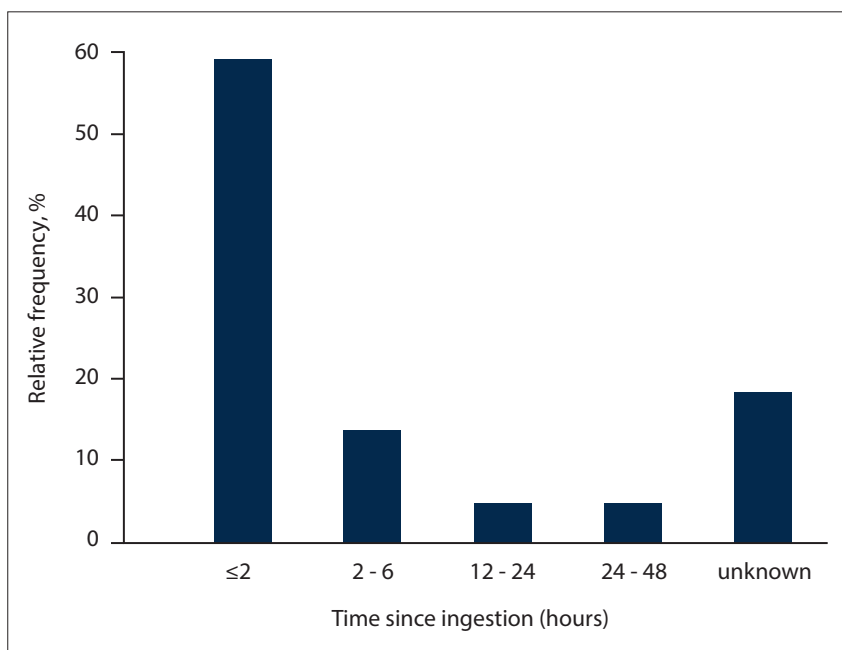


Fig. 4. Time between ingestion of button battery and presentation.

button battery ingestions required surgical removal under general anaesthesia in the operating theatre, with varying levels of morbidity. In one noteworthy case, delayed presentation led to migration of a button battery from the oesophagus into the trachea with partial compression of the great vessels, requiring cardiopulmonary bypass and deep hypothermic circulatory arrest for removal and repair.^[5]

These data are directly comparable to the cohorts from the same tertiary centre and database published previously, for periods spanning 1991 - 2000,^[1] 1991 - 2009^[16] and

2010.^[3] When taking all foreign bodies into account, the distributions of age and gender were similar across all four studies. In the index study, Van As *et al.*^[1] specifically examined 241 foreign bodies from 2001 and 2002, finding coins the most common object, and metal the most common material. They did not report a specific rate of battery ingestion. However, Timmers *et al.*^[16] expanded upon these data, reporting on 8 149 cases over an 18-year period with a nearly identical age and gender distribution to our data. Again, coins were the most frequently ingested (40.8%), but they also

reported a 2.1% (n=119) incidence of battery ingestion. Commenting that this figure was low compared with other international studies, the authors hypothesised that it might have been due to the relative scarcity of battery-operated toys in SA at the time. Delpont *et al.*^[3] examined the database for 1 year (2010; n=146), overlapping with the data set in this study. Overall patterns were again consistent with the other studies, with coins the most frequently ingested object. Furthermore, they examined all available chest radiographs (202 performed on 137 children) to confirm objects and anatomical location. Batteries were reported to comprise 5% of ingestions. This figure is in keeping with a rate of 5.6% found in 3 years of data from Pietermaritzburg (2012 - 2014; n=105) recently published by Majola *et al.*^[4] The subtype of battery was not reported in any of these prior studies.

In contrast to the SA studies, the international data are extensive, and show a convincing increasing trend in battery and button battery ingestion, with the latter far more common than cylindrical cells.^[9] Mowry *et al.*^[14] reported a 2.5-fold increase in cases from 1998 - 2010, with Litovitz^[10] demonstrating a 6.7-fold increase in major morbidity or fatal outcomes.^[9] These trends have been confirmed in further reviews, leading to the establishment of a Button Battery Task Force in the USA, with engagement from the medical fraternity, battery industry and government.^[10-13,17] The increased morbidity and greater need for admission, anaesthesia and surgery in our local data are in keeping with these trends.

Globally, button battery ingestion is recognised to be particularly concerning owing to the rapidity and extent of the resulting injuries.^[12,18,19] While most foreign bodies cause harm only by obstruction and physical trauma, the electrochemical effects of these compact batteries result in rapid formation of an electrical circuit, production of hydroxide ions, alkaline burns, fat saponification and liquefactive necrosis.^[6,7] Severity of injury is directly related to battery type, voltage and duration of exposure. Injury can be noted in as little as 15 minutes, with recommendations stating that removal should occur ideally within 2 - 6 hours,^[12,13] which requires a high index of suspicion and rapid diagnostic imaging.

The very high incidence of coin ingestion is meaningful in this context. Because of the similarity in form, physical and radiological appearance of button batteries and coins, the two may be easily confused by parents and

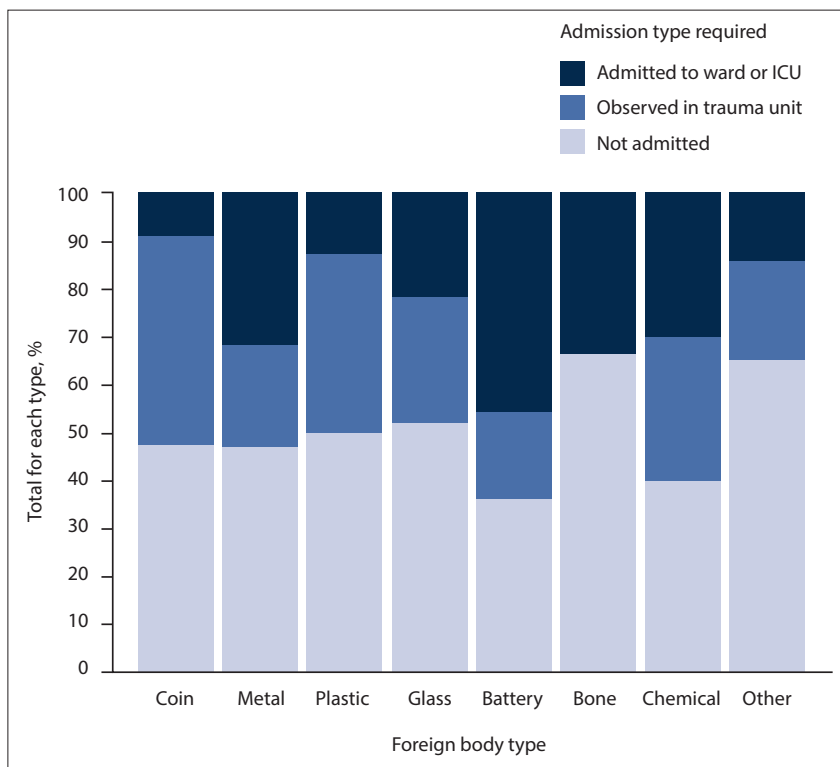


Fig. 5. Type of admission required based on object ingested.

clinicians alike. All suspected coin ingestions should therefore be carefully investigated before an expectant management plan is instigated. Any coin-like round opacities found on radiographs should be closely inspected for a halo, double-ring or step appearance that would indicate a button battery rather than a coin.^[12,13] Lateral X-rays may demonstrate the narrower side of the battery, corresponding to the negative terminal at which the most severe tissue damage occurs;^[10] this may assist planning for surgical intervention, but should not delay rapid removal.

The present report strengthens the understanding of this patient cohort by including admissions that were directly referred to the surgical wards, and therefore bypassed the trauma unit. This routing may account for the greater rate of battery ingestion than in the period published by Timmers *et al.*,^[16] although a true increase in rate is also feasible. However, as a retrospective study, it has several weaknesses. The information gathered in the trauma unit database is limited, and relies upon busy clinicians, with high patient and staff turnover. Furthermore, the admissions database records have few medical details. As described above, foreign bodies are frequently incorrectly categorised or inadequately described. In the case of batteries, the type was not routinely

documented. Further management and outcomes could at times be discerned from the clinical notes, but we were generally unable to access information on where foreign bodies had become lodged, specific measures related to diagnosis and removal, and the complications associated. A specific prospective registry of these cases is needed to improve the quality of the data for future studies.

Conclusions

Although SA data on battery ingestion are scarce, this study demonstrates that the incidence may be increasing. Admission, anaesthesia and surgery rates for batteries were higher in this cohort than for all other foreign bodies. In particular, the confirmed predominance of button batteries, combined with increased morbidity and universal requirement for operative removal in these identified cases, is concerning.

Our ability to expedite diagnosis and removal hinges on a high index of suspicion. The data strengthen the understanding that children under 3 years of age are most at risk. The large proportion who present early is reassuring, as the critical time to removal is within 2 hours. However, it remains imperative to increase awareness among healthcare workers and parents to expedite presentation, diagnosis and removal.

Declaration. This study was undertaken in partial completion of the degree MMed (Anaes) at the University of Cape Town (candidate JAC; supervisors JT and RH).

Acknowledgements. The authors acknowledge the staff of Red Cross War Memorial Children's Hospital and the Western Cape Department of Health for their work and ongoing promotion of child health, and Prof. Sebastian van As for assistance with the database.

Author contributions. JAC: study conception, literature review, data collection, manuscript preparation. JT: study conception, co-supervision, manuscript review. RH: supervision, data analysis and figure preparation, manuscript editing and review.

Funding. This research was supported by departmental funding.

Conflicts of interest. None.

1. Van As AB, du Toit N, Wallis L, et al. The South African experience with ingestion injury in children. *Int J Pediatr Otorhinolaryngol* 2003;67(Suppl 1):S175-S178. <https://doi.org/10.1016/j.ijporl.2003.08.021>
2. Dereci S, Koca T, Serdaroglu F, et al. Foreign body ingestion in children. *Turk Pediatr Ars* 2015;50(4):234-240. <https://doi.org/10.5152/TurkPediatrArs.2015.3164>
3. Delpont CD, Hodgkinson PW, Cheema B. Investigation and management of foreign body ingestion in children at a major paediatric trauma unit in South Africa. *Afr J Emerg Med* 2015;5(4):176-180. <https://doi.org/10.1016/j.afjem.2015.06.004>
4. Majola NF, Kong VY, Mangray H, et al. An audit of ingested and aspirated foreign bodies in children at a university hospital in South Africa: The Pietermaritzburg experience. *S Afr Med J* 2018;108(3):205-209. <https://doi.org/10.7196/SAMJ.2018.v108i3.12590>
5. Hofmeyr R, Bester K, Willms A, et al. Tracheoesophageal fistula following button battery ingestion in an infant: Airway management considerations. *Anaesthetist* 2019;68:777-779. <https://doi.org/10.1007/s00101-019-00679-4>
6. Yasui T. Hazardous effects due to alkaline button battery ingestion - an experimental study. *Ann Emerg Med* 1986;15(8):901-906. [https://doi.org/10.1016/S0196-0644\(86\)80672-2](https://doi.org/10.1016/S0196-0644(86)80672-2)
7. Yoshikawa T, Asai S, Takekawa Y, et al. Experimental investigation of battery-induced esophageal burn injury in rabbits. *Crit Care Med* 1997;25(12):2039-2044. <https://doi.org/10.1097/00003246-199712000-00022>
8. Tanaka J, Yamashita M, Yamashita M, et al. Esophageal electrochemical burns due to button type lithium batteries in dogs. *Vet Hum Toxicol* 1998;40(4):193-196.
9. Litovitz T, Whitaker N, Clark L. Preventing battery ingestions: An analysis of 8648 cases. *Pediatrics* 2010;125(6):1178-1183. <https://doi.org/10.1542/peds.2009-3038>
10. Litovitz T, Whitaker N, Clark L, et al. Emerging battery-ingestion hazard: Clinical implications. *Pediatrics* 2010;125(6):1168-1177. <https://doi.org/10.1542/peds.2009-3037>
11. Sharpe SJ, Rochette LM, Smith GA. Pediatric battery-related emergency department visits in the United States, 1990-2009. *Pediatrics* 2012;129(6):1111-1117. <https://doi.org/10.1542/peds.2011-0012>
12. Jatana KR, Litovitz T, Reilly JS, et al. Pediatric button battery injuries: 2013 task force update. *Int J Pediatr Otorhinolaryngol* 2013;77(9):1392-1399. <https://doi.org/10.1016/j.ijporl.2013.06.006>
13. Leinwand K, Brumbaugh DE, Kramer RE. Button battery ingestion in children: A paradigm for management of severe pediatric foreign body ingestions. *Gastrointest Endosc Clin N Am* 2016;26(1):99-118. <https://doi.org/10.1016/j.giec.2015.08.003>
14. Mowry JB, Spyker DA, Cantilena LR Jr, et al. 2013 Annual report of the American Association of Poison Control Centers' National Poison Data System (NPDS): 31st Annual Report. *Clin Toxicol (Phila)* 2014;52(10):1032-1283. <https://doi.org/10.3109/15563650.2014.987397>
15. Statistics South Africa. Community Survey 2016 - Provinces at a Glance. Pretoria: StatsSA; 2016:31. <http://cs2016.statssa.gov.za/wp-content/uploads/2016/06/CS-2016-Provinces-at-a-glance.pdf> (accessed 11 November 2019).

16. Timmers M, Snoek KG, Gregori D, et al. Foreign bodies in a pediatric emergency department in South Africa. *Pediatr Emerg Care* 2012;28(12):1348-1352. <https://doi.org/10.1097/PEC.0b013e318276c20e>
17. Marom T, Goldfarb A, Russo E, et al. Battery ingestion in children. *Int J Pediatr Otorhinolaryngol* 2010;74(8):849-854. <https://doi.org/10.1016/j.ijporl.2010.05.019>
18. Litovitz T, Butterfield AB, Holloway RR, et al. Button battery ingestion: Assessment of therapeutic modalities and battery discharge state. *J Pediatr* 1984;105(6):868-873. [https://doi.org/10.1016/s0022-3476\(84\)80068-2](https://doi.org/10.1016/s0022-3476(84)80068-2)
19. Sahin A, Meteroglu F, Erbey A, et al. Insidious threat of children: Esophageal foreign body ingestion. *J Acad Emerg Med* 2014;13(4):159.

Accepted 7 January 2020.