



Choledochal malformations: Lessons learnt in Johannesburg

A Grieve, MB BCh, MMED (Surgery), FC Paed Surg (SA); D Harrison, BSc, MB ChB, MMed (Surgery), FC Paed Surg (SA);
C Westgarth-Taylor, BSc (Hon), MB ChB, MRCS, FC Paed Surg (SA); J Loveland, MB BCh, FCS (SA), Cert Paed Surg (SA)

Department of Paediatric Surgery, Faculty of Health Sciences, University of the Witwatersrand, Johannesburg, South Africa

Corresponding author: A Grieve (a.grieve@me.com)

Background. Choledochal malformation (CM) is a well-described and relatively rare condition. CMs may present on antenatal ultrasound screening, through childhood and into adulthood. The aetiology is not well understood but the association with a pancreaticobiliary malunion predisposes to the development of CMs.

Objectives. To review the experience of CMs in the Department of Paediatric Surgery, University of the Witwatersrand, Johannesburg to improve our patient care for this population.

Methods. After institutional ethics approval, a retrospective record review was conducted of patients presenting with CM to the Department of Paediatric Surgery, Faculty of Health Sciences, University of the Witwatersrand, Johannesburg. All patients managed between January 2010 and May 2017 were included.

Results. A total of 35 patients underwent surgery for CMs and 2 patients were excluded from the study owing to incomplete records. Most of our patients (83%) presented with jaundice and a median (interquartile range) bilirubin level of 167 (32 - 234) $\mu\text{mol/L}$. In our cohort of patients those with type IV lesions presented at a younger age and with higher bilirubin and gamma-glutamyl transferase levels, although this finding was not statistically significant.

Conclusion. Although uncommon, CMs may lead to significant morbidity and malignancy. Specialised care is necessary to improve long-term outcomes in these patients.

S Afr Med J 2017;107(11 Suppl 1):S23-S25. DOI:10.7196/SAMJ.2017.v107i11.12895

Choledochal malformations (CMs) are defined as dilatations of the biliary tree in various distributions and configurations. The majority are found in the extrahepatic ducts, but certain types (IVa and V) involve the intrahepatic biliary tree. The incidence of CM varies around the world, with the incidence in the United States of America reported as 1:150 000, the Netherlands 1:59 000 and in Asia as 1:10 000.^[1] Currently, there are no reliable data reflecting the incidence of CM in South Africa.

Three patterns of presentation have been identified in childhood. During the antenatal period lesions may be identified during routine ultrasound screening as a cystic mass in the porta hepatis. After birth, cysts may present during two broad time frames, either in infancy when they typically present with jaundice and a palpable right upper quadrant mass, or later in childhood with features of obstructive jaundice, cholangitis or pancreatitis.

Alonso-Lej *et al.*^[2] initially described two types of CM. Todani *et al.*^[3] later expanded the classification to include intrahepatic and multiple cysts. They described 5 different subtypes depending on the location (extrahepatic, intrahepatic, or a combination of the two) and shape (cystic or fusiform) of the malformation: type I is a cystic or fusiform dilatation of the extrahepatic biliary system; type II is a diverticulum coming off the common bile duct; type III is a choledochoceles involving dilatation at the distal tip of the bile duct; type IV is a dilatation of the extra- and intrahepatic ductal system; and type V involves intrahepatic duct dilatation with or without liver fibrosis.

The typically described trio of pain, a right upper quadrant mass lesion and jaundice is rarely seen in our population. The spectrum of presentation of CM is varied, ranging from an asymptomatic child who is incidentally diagnosed to patients presenting with obstructive symptoms including stone formation, cholangitis and

pancreatitis. Although these early complications are often the reason for presentation and subsequent management, asymptomatic cysts are also resected to negate the risk of developing cholangiocarcinoma in later years.^[4]

Methods

We performed a retrospective record review of all patients with the diagnosis of a CM treated at the Department of Paediatric Surgery, Faculty of Health Sciences, University of the Witwatersrand between January 2010 and May 2017. Ethics approval was granted by the University of the Witwatersrand Human Research Ethics Committee (ref. no. M170646).

Results

Over the 7.5-year study period, 35 patients were identified but only 33 were included in the study owing to incomplete clinical records for 2 of the patients. All of the patients had undergone resection of the cyst with reconstruction using a Roux-on-Y hepatico-jujenostomy. The median (interquartile range (IQR)) age at surgery was 31 (4 - 60) months. Most of our patients (83%; $n=27$) presented with jaundice and a median (IQR) bilirubin concentration of 167 (32 - 234) $\mu\text{mol/L}$ and a raised median (IQR) gamma glutamyl transferase concentration of 706 (282 - 1 233) IU/L. A total of 26 patients had their lesions classified according to Todani *et al.*^[3] – there were 19 type I lesions and 7 type IVa lesions. Patients with type IV lesions presented at a younger age (Fig. 1) and with higher bilirubin levels (Fig. 2), although this finding was not statistically significant.

Discussion

Types I and IV CM are most likely to present with obstructive symptoms^[5] as seen in 83% of our patients. These lesions are also

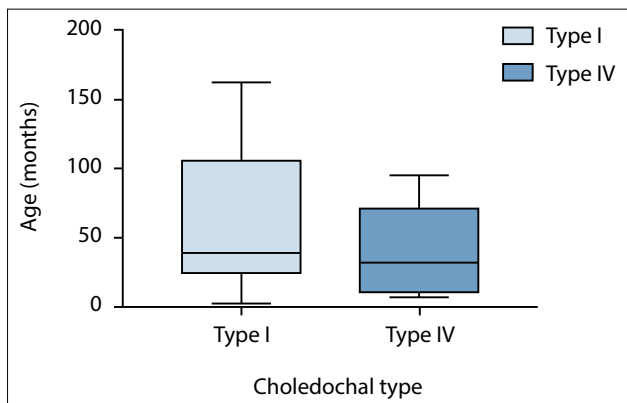


Fig. 1. Choledochal malformation type v. age at presentation.

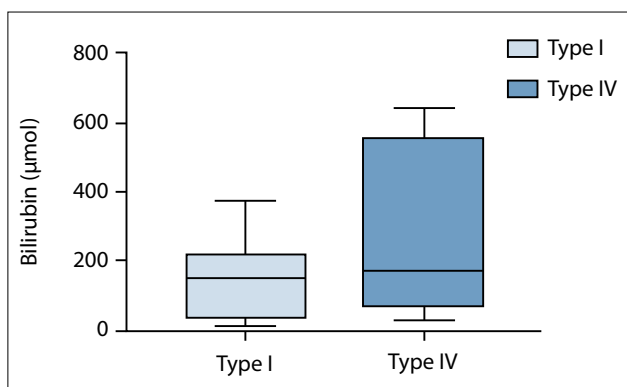


Fig. 2. Choledochal malformation type v. bilirubin level at presentation.

more commonly associated with the anomalous pancreaticobiliary malunion described by Babbitt in 1969.^[6] As the length of the common channel increases, the ampulla of Vater is found progressively more distally in the duodenum.^[7] This anomalous anatomy results in increased reflux of pancreatic and biliary secretions into the proximal common bile duct, causing inflammation and stone formation. These preceding insults result directly in obstructive jaundice, pancreatitis and an increased risk of malignancy in the biliary tree. The pathogenesis of cholangiocarcinoma in this setting remains debatable. It is postulated that the combination of refluxed pancreatic juice and biliary stasis is pathological and causes acute inflammation, which progresses to chronic inflammation that renders the biliary epithelium susceptible to the development of cholangiocarcinoma.^[8] Presentation with cholangiocarcinoma in CM during childhood is reported in 0.42% of cases compared with 11.4% in adults. It is prudent to note that once surgical resection and reconstruction for CM has taken place, there is still a 14% risk of developing malignant disease later in life.^[9]

Other congenital anomalies are not frequently associated with CM. However, Murphy *et al.*^[10] described associated cardiac anomalies in 44.9% of CM who presented under the age of 1 year. This association decreased to 6.9% in the older age group. Routine cardiac screening using an echocardiogram should be considered in patients younger than 12 months of age with a CM.

The clinical differentiation between type I and type IVa cysts is difficult. Careful consideration must be given to whether the intrahepatic ductal dilatation is secondary to biliary obstruction from the extrahepatic component, thus making it a type I or whether there is pathological separate intrahepatic dilatation, with or without stricturing in the proximal hepatic ductal system as in type IVa.^[11] This diagnostic doubt can result in classification issues, as well as

leading to discrepant surgical management of these cases. In type IVa cases with an identifiable stricture, percutaneous transhepatic cholangiography with biliary balloon dilatation may be considered, as may open stricturoplasty. If there is localised intrahepatic duct dilatation surgeons may consider localised liver resection in conjunction with resection of the extrahepatic component of the CM.

In cases where no stricture is noted and focal intrahepatic biliary dilatation occurs that is thought to be pathological, resection of the extrahepatic component of the CM resection is undertaken with close follow-up to determine resolution of the dilated intrahepatic segments.

Diao *et al.*^[12] demonstrated no stage IV fibrosis on neonates operated on under 1 month of age, but a 25% incidence of stage IV fibrosis in their cohort of infants operated on after 1 month of age ($p=0.03$). Their group demonstrated no difference in perioperative morbidity between the two groups, confirming the feasibility and safety of surgery in this younger population. With the increase in the availability of antenatal ultrasound screening and earlier detection of CM, neonatal surgery should be strongly considered.

In our experience, the diagnosis can be made with an ultrasound in most cases when taking into account the clinical and laboratory associations. We have not found magnetic resonance cholangiopancreatography (MRCP) to be beneficial in neonates and infants owing to the difficulty in tissue differentiation and poorly reconstructed 3D images; however, in the older group of children, MRCP aids the diagnosis of anomalies of biliary anatomy and also the planning of the intra-operative biliary reconstruction. In patients where pre-operative MRCP is not suitable, an on-table cholangiogram provides the ductal road map demonstrating aberrant hepatic ductal variations that require alternative reconstruction planning.

Management involves removing the involved segment of the biliary tree but cognisance must be given to the small nuances that may lead to morbidity if neglected.^[13] Removal of the entire involved common bile duct often necessitates entering the head of the pancreas with care not to damage the pancreatic duct. Although some units advocate insertion of a choledochal scope to visualise and remove any stones in both the distal and proximal ducts, we generally find that irrigation of the proximal ductal structures is sufficient. In the majority of type I and IVa CMs, the distal duct is completely obliterated and there is no need to suture-ligate the distal duct unless patency is observed.

In Johannesburg, the incidence of bile stones is rare and the majority of patients present with large amounts of sludge in the choledochal cyst. This sludge still results in obstructive symptomatology and should thus be washed out. Shorter Roux-on-Y limbs may be utilised in patients with CM as compared with those with biliary atresia. The enteric anastomosis is performed as an end-side, or end-end anastomosis taking care not to cause narrowing of the anastomosis. End-to-side anastomoses should be close to the limb end to avoid a blind-ending limb and subsequent stasis.

There have been remarkable advancements in the field of paediatric laparoscopic surgery. Multiple centres have embarked on endoscopic CM surgery and continue to do so; the advantages include decreased length of hospital stay and improved cosmesis. However, the literature has shown a large increase in the short-term complications and concern over the long-term increased risk of malignancy secondary to incomplete excision.

In 2017, Stringer^[13] reported on the evidence for lower biliary anastomosis in endoscopic reconstructions resulting in increased stricture rates requiring redo surgery, difficult visualisation of the distal duct remnant resulting in a large distal duct remnant being left *in situ*, and increased incidence of vascular injuries in endoscopic procedures. Most endoscopic surgeons propose the use of hepatico-

duodenostomy over the conventional Roux-on-Y reconstruction owing to its ease in performing endoscopically. However, this predisposes patients to bile reflux and gastritis, with a potential increased risk of gastric malignancies. Stringer^[17] also remarks that laparoscopic CM resections are often delayed until after 1 year of age to facilitate a technically easier procedure; however, increased liver damage is established during this waiting period. It seems that robotic surgery is not exempt from these problems, with an incidence of 14% early complication rates.^[14]

Conclusion

CMs have a low incidence in the general population but are commonly seen in paediatric surgical practice. Early surgery protects the liver from advanced fibrosis and can be performed safely with the correct support services.

Long-term follow-up is mandatory as the risk of malignancy is not completely mitigated by resection of the CM.

Acknowledgements. We would like to thank Ansie Welthagen and Martene Esteves for their help with some of the data collection.

Author contributions. AG conceived the research topic, identified the patients, collected the data, reviewed the literature and wrote the manuscript. DH and CWT edited the manuscript and contributed to the discussion. JL edited and co-authored the manuscript.

Funding. None.

Conflicts of interest. None.

1. Nederlandse Studiegroep voor Choledochus Cysten/malformaties (NeSCHoC), Van den Eijnden MHA, De Kleine RHJ, et al. Choledochal malformation in children: Lessons learned from a Dutch national study. *World J Surg* 2017;41(10):2631-2637. <https://doi.org/10.1007/s00268-017-4064-x>
2. Alonso-Lej F, Rever WB, Pessagno DJ. Congenital choledochal cyst, with a report of 2, and analysis of 94, cases. *Int Abstr Surg* 1959;108(1):1-30.
3. Todani T, Watanabe Y, Narusue M, et al. Congenital bile duct cysts: Classification, operative procedures, and review of thirty-seven cases including cancer arising from choledochal cyst. *Am J Surg* 1977;134:263-269. [https://doi.org/10.1016/0002-9610\(77\)90359-2](https://doi.org/10.1016/0002-9610(77)90359-2)
4. Gonzales KD, Lee H. Choledochal cyst. In: Coran AG, ed. *Pediatric Surgery*. 7th ed. Philadelphia: Elsevier, 2012:1331-1339.
5. Soares KC, Goldstein AD, Ghaseb MA, et al. Pediatric choledochal cysts: Diagnosis and current management. *Pediatr Surg Int* 2017;33:637-650. <https://doi.org/10.1007/s00383-017-4083-6>.
6. Babbit DP. Congenital choledochal cysts: New etiological concept based on anomalous relationships of the common bile duct and pancreatic bulb. *Ann Radiol* 1969;12(3):231-240.
7. Li L, Yamataka A, Yian-Xia W, et al. Ectopic distal location of the papilla of Vater in congenital biliary dilatation: Implications for pathogenesis. *J Pediatr Surg* 2001;36(11):1617-1622. <https://doi.org/10.1053/jpsu.2001.27932>
8. Singham J, Yoshida EM, Scudamore CH. Choledochal cysts. Part 1 of 3: Classification and pathogenesis. *Can J Surg* 2009;52(5):434-440.
9. Ono S, Fumino S, Shimadera S, Iwai N. Long-term outcomes after hepaticojejunostomy for choledochal cysts: A 10- to 27-year follow-up. *J Pediatr Surg* 2010;45(2):376-378. <https://doi.org/10.1016/j.jpedsurg.2009.10.078>
10. Murphy AJ, Axt JR, Lovvorn HN. Associations between pediatric choledochal cysts, biliary atresia and congenital cardiac anomalies. *J Surg Res* 2012;177(2):e59-63. <https://doi.org/10.1016/j.jss.2012.04.018>
11. Todani T, Watanabe Y, Toki A, et al. Classification of congenital biliary cystic disease: Special reference to type Ic and IVA cysts with primary ductal stricture. *J Hepatobiliary Pancreatic Surg* 2003;10(5):340-344. <https://doi.org/10.1007/s00534-002-0733-7>
12. Diao M, Li L, Cheng W. Timing of surgery for prenatally diagnosed asymptomatic choledochal cysts: A prospective randomised study. *J Pediatr Surg* 2012;47(3):506-512. <https://doi.org/10.1016/j.jpedsurg.2011.09.056>
13. Stringer MD. Laparoscopic management of choledochal cysts: Is keyhole view missing the big picture? *Pediatr Surg Int* 2017;33(6):651-655. <https://doi.org/10.1007/s00383-017-4089-0>
14. Kim NY, Chang EY, Hong YJ, et al. Retrospective assessment of the validity of robotic surgery in comparison to open surgery for pediatric choledochal cyst. *Yonsei Med J* 2015;56:737-743. <https://doi.org/10.3349/ymj.2015.56.3.737>

Accepted 29 September 2017.

